# The Testicular Sperm Ducts and Genital Kidney of Male *Ambystoma maculatum* (Amphibia, Urodela, Ambystomatidae)

**Dustin S. Siegel,[1]* Robert D. Aldridge,[2] Justin L. Rheubert,[2] Kevin M. Gribbins,[3] David M. Sever,[4] and Stanley E. Trauth[5]**

[1]*Department of Biology, Southeast Missouri State University, Cape Girardeau, Missouri 63701*
[2]*Department of Biology, Saint Louis University, St. Louis, Missouri 63103*
[3]*Department of Biology, Wittenberg University, Springfield, Ohio 45501*
[4]*Department of Biological Sciences, Southeastern Louisiana University, Hammond, Louisiana 70402*
[5]*Department of Biological Sciences, Arkansas State University, State University, Arkansas 72467*

*ABSTRACT* The ducts associated with sperm transport from the testicular lobules to the Wolffian ducts in *Ambystoma maculatum* were examined with transmission electron microscopy. Based on the ultrastructure and historical precedence, new terminology for this network of ducts is proposed that better represents primary hypotheses of homology. Furthermore, the terminology proposed better characterizes the distinct regions of the sperm transport ducts in salamanders based on anatomy and should, therefore, lead to more accurate comparisons in the future. While developing the above ontology, we also tested the hypothesis that nephrons from the genital kidney are modified from those of the pelvic kidney due to the fact that the former nephrons function in sperm transport. Our ultrastructural analysis of the genital kidney supports this hypothesis, as the basal plasma membrane of distinct functional regions of the nephron (proximal convoluted tubule, distal convoluted tubule, and collecting tubule) appear less folded (indicating decreased surface area and reduced reabsorption efficiency) and the proximal convoluted tubule possesses ciliated epithelial cells along its entire length. Furthermore, visible luminal filtrate is absent from the nephrons of the genital kidney throughout their entire length. Thus, it appears that the nephrons of the genital kidney have reduced reabsorptive capacity and ciliated cells of the proximal convoluted tubule may increase the movement of immature sperm through the sperm transport ducts or aid in the mixing of seminal fluids within the ducts. J. Morphol. 274:344–360, 2013. 

KEY WORDS: urogenital; nephron; anatomy; histology; ultrastructure

## INTRODUCTION

The kidney of male salamanders can be divided into pelvic and genital kidney segments (Siegel et al., 2010). Whereas the caudally positioned pelvic kidney is responsible for filtration and urine formation, the more cranially positioned genital kidney is responsible for sperm transport from the testes to the Wolffian ducts in all salamanders (Spengel, 1876). Although terminology of the sperm passage ducts is variable in different taxonomic groups, this condition is the plesiomorphic morphology of terrestrial vertebrate kidneys and appeared first in their marine ancestors (Jones, 2001).

Williams et al. (1984) and Aranzábal (2003, 2009) reviewed the histology of the testicular sperm ducts and genital kidney nephrons in salamanders. These ducts include what have traditionally been termed the testicular sperm ducts (central testicular canal and associated ducts), vasa efferentia, longitudinal collecting duct (Bidder's duct), afferent epididymal ducts, the genital kidney (epididymal nephrons), and efferent epididymal ducts. According to Williams et al. (1984) and Aranzábal (2003, 2009), testicular sperm ducts transfer sperm from the testicular lobules, which subsequently transfer sperm into the vasa efferentia. Sperm then travel from the vasa efferentia to the afferent epididymal ducts (delineated by a longitudinal canal that connects serially aligned vas efferens branches in most salamanders) that transfer sperm into the genital kidney nephrons. The genital kidney nephrons then transfer sperm into the efferent epididymal ducts that transport sperm to the Wolffian duct (see Fig. 3, p 327, Williams et al., 1984). The above represents the general configuration of the testicular ducts and genital kidney nephrons in most salamanders; however, variation has been observed in some taxa; for example,

*Correspondence to: Dustin S. Siegel, Department of Biology, Southeast Missouri State University, One University Plaza MS6200, Cape Girardeau, MO 63701.
E-mail: dsiegel@semo.edu

Received 26 July 2012; Revised 10 September 2012; Accepted 6 October 2012

Published online 29 November 2012 in Wiley Online Library (wileyonlinelibrary.com)
DOI: 10.1002/jmor.20100

*TABLE 1. Historical and proposed terminology for the testicular and genital kidney ducts in salamanders*

| | Figure 1 key | | | | | | | | | | |
|---|---|---|---|---|---|---|---|---|---|---|---|
| | a | b | c | d | e | f | g | h | I | j | k |
| Spengel (1876)[a–g] | Sammelgang (collecting duct) | Quercanale (cross canal) | Läugscanal des Hodennetzes (longitudinal canal of testicular network) | Vasa efferentia | Malpighische Körperchen | Hals (neck) | zweiter Abschnitt des Harncanäl chens (second section)[h] | | | Sammelrohren (collecting pipes) | Leydigscher Gang (Leydig's duct) |
| Chase (1923)[a] | Central testicular canal | Vas efferens testis (ductuli efferentes) | Collecting duct of kidney | Transverse trunk | Renal (malpighian) corpuscle | Ciliated neck | Proximal convoluted part of renal tubule | Narrow part of the renal tubule | Distal convoluted part of renal tubule | Junctional part of renal tubule | Wolffian duct |
| Yamagiwa (1924)[i] | Sammelgang des Hodens (collecting duct of testis) | Vasa efferentia | Längskanal (longitudinal canal) | NA[j] | Malpighische Körperchen | Geschlechtsniere (genital kidney) or Nierenkanälchen (renal tubules) | | | | Sammelröhrchen der Geschl-echtsniere (collecting tubule of the genital kidney) | Wolffscher Gang (Wolffian duct) |
| McCurdy (1931)[e] | Longitudinal canal of the testis | Vasa efferentia | Longitudinal canal of the kidney | "Connection between the longitudinal canal and the renal orpuscle" | Renal corpuscle | Neck of kidney tubule | Kidney tubule | | | | Wolffian duct |
| Francis (1934)[e] | ? | Vasa efferentia | Bidder's duct | Connecting ducts | Bowman's capsule | Sexual kidney | | | | | Wolffian duct |
| Rodgers and Risley (1938)[f] | ? | Vasa efferentia | Bidder's canal | NA | Sexual kidney | | | | | | Wolffian duct |
| Baker and Taylor (1964)[f] | Longitudinal (central) duct | Vasa efferentia | Longitudinal (marginal) duct | Afferent epididymal duct | NA | Efferent epididymal duct | | | | | Wolffian duct |
| Baker (1965)[e] | ? | Vasa efferentia | Longitudinal canal | Afferent epididymal duct | Renal corpuscle | Efferent epididymal duct | | | | | Wolffian duct |
| Ratcliff (1965)[b] | ? | Vasa efferentia | Longitudinal canal | Afferent epididymal duct | Glomerulus | Efferent epididymal duct | | | | | Wolffian duct |

*TABLE 1. (Continued)*

| | Figure 1 key | | | | | | | | | | |
|---|---|---|---|---|---|---|---|---|---|---|---|
| | a | b | c | d | e | f | g | h | I | j | k |
| Willett (1965)[c] | Absent (spherical ampullae connected by rete testis) | Vasa efferentia | NA | ? | Glomerulus in Bowman's capsule | Neck segment[k] | Proximal convolution[k] | ? | Distal convolution[k] | | Wolffian duct |
| Strickland (1966)[g] | ? | Vasa efferentia | NA | ? | NA | Epididymis | | | | Efferent epididymal tubule[l] | Vas deferens |
| Rosenquist and Baker (1967)[a] | Longitudinal collecting canal of the testes | Vasa efferentia | Bidder's duct | Afferent epididymal duct | Glomerulus | Ciliated collecting tubule | Proximal convolution | ? | Distal convolution | Efferent epididymal duct | Wolffian duct |
| Williams et al. (1984)[m] | Central testicular canal | Vasa efferentia | Longitudinal collecting duct | Afferent epididymal duct | Epididymal renal corpuscle | Efferent epididymal duct | | | | | Vas deferens |
| Williams et al. (1984)[n] | Central testicular canal | Transverse tubule[o] | | | | | | | | | Vas deferens |
| Aranzábal (2003)[m] | Intratesticular efferent ducts | Transversal efferent ducts (including a Bidder's duct and cranial kidney nephrons except in Plethodontidae) | | | | | | | | | Wolffian duct |
| Proposed terminology | Testicular ducts | Vasa efferentia | | | Genital RC | Genital Ns | Genital Pct | Genital Is | Genital Dct | Genital Ct | Wolffian duct |

Abbreviations: Ct, collecting tubule; Dct, distal convoluted tubule; Is, intermediate segment; Ns, neck segment; Pct, proximal convoluted tubule; Rc, renal corpuscle. "?" – unknown; that is, the authors provide no terminology for this region, but the region appears in figures or is discussed in text. "NA" – not applicable; i.e., this region does not exist in the examined taxa.

[a]Proteidae.
[b]Cryptobranchidae.
[c]Sirenidae.
[d]Amphiumidae.
[e]Salamandridae.
[f]Ambystomatidae.
[g]Plethodontidae.
[h]Spengel (1876) does not discuss the regionality of the genital kidney nephrons in text but does label the regions distal to the neck as the "zweiter Abschnitt des Harncanälchens."
[i]Hynobiidae.
[j]Yamagiwa (1924) does not create terminology for the ducts that leads from what is often termed the Bidder's duct to the renal corpuscle, as the figures from Yamagiwa (1924) depict the renal corpuscles arising directly from the medial side of the Bidder's ducts.
[k]Willett (1965) only uses the terms proximal and distal convolutions for labeling purposes; in text, she refers to the region collectively as the epididymal tubule.
[l]Strickland (1966) does not label efferent epididymal tubules but does note that a different tubule empties the epididymal contents into the Wolffian duct.
[m]Review—terminology synthesized from multiple taxa.
[n]Review—terminology synthesized only from Plethodontidae.
[o]Williams et al. (1984) do not hypothesize the homology of the transverse tubule of plethodontids with any one region of the epididymal complex from other salamander families, but simply state that no regionality is observed along the length of the duct that adjoins the testis to the vas deferens.

the lack of regionality along the sperm transport ducts in plethodontids (Williams et al., 1984) and rhyacotritonids (Siegel et al., 2012a).

As depicted by Willett (1965; see Plate 1, p 11) in sirenids, stereotypical regions of the nephron can be observed in the genital kidney nephron of salamanders. Regions include a renal corpuscle (with glomerulus), neck segment, proximal convoluted tubule, intermediate segment, distal convoluted tubule, and collecting tubule. This pattern appears to be consistent with the majority of salamander taxa (Spengel, 1876; Yamagiwa, 1924; Baker, 1965; Ratcliff, 1965; Rosenquist and Baker, 1967; Williams et al., 1984). Thus, regions of the nephron observed in the pelvic kidney (Clothier et al., 1978; Siegel et al., 2010) are also observed in the genital kidney of salamanders. However, the pelvic kidney also features a segment distal to the collecting tubule, the collecting duct, which hypertrophies and produces an abundant secretion in some salamander lineages during the mating season (Siegel et al., 2010, 2012b). Because the regionality of these ducts differs little between the two distinct kidney regions, Spengel (1876) hypothesized that the genital kidney nephrons were capable of producing urine and transporting sperm.

Currently, no study has investigated the ultrastructure of the testicular sperm ducts and genital kidney of male salamanders. In this investigation, we utilized transmission electron microscopy to evaluate the ultrastructure of all the distinct regions of the cranial sperm transport complex in male *Ambystoma maculatum*. The purpose of this investigation was twofold: 1) to develop a detailed ontology of the cranial sperm transport complex in male salamanders to facilitate future comparisons between taxa and 2) to test the hypothesis that genital kidney nephrons are modified for sperm transport by comparing the cellular morphology of genital kidney nephrons with those of pelvic kidney nephrons (recently described in detail by Siegel et al., 2010).

## MATERIALS AND METHODS

Four male *A. maculatum* were utilized from the Saint Louis University Museum collection. These were the same specimens used in Siegel et al. (2010). Snout vent lengths ranged from 78 to 80 mm. Two of these individuals were captured in a pond on March 18, 2010 in Crawford County, Missouri and were injected with McDowell's-Trump fixative (Electron Microscopy Sciences, Hatfield, PA) followed by immersion in the same fixative for 4 h. After initial fixation the urogenital tracts were removed and immersed in a second solution of McDowell's Trump fixative for 48 h. The left urogenital tract was then rinsed and dehydrated via increasing concentrations of ethanol (35, 70, 95, and 100%), cleared with toluene, immersed in melted paraplast under vacuum for 12 h, and embedded in paraffin wax. Transverse sections were made at 7 μm, affixed to slides with albumen, and stained with hematoxylin and eosin for general structural analysis following the protocols of Kiernan (1990). Slides were viewed with an Olympus BX40 compound microscope (Olympus Corporation of the America, Center Valley, PA) and micrographs were obtained via a Canon T3i digital camera (Canon USA, Lake Success, NY) attached to the microscope via a custom T-mount adapter (Martin Microscope, Easley, SC). Images were subsequently uploaded into Adobe Creative Suite 5.5 (Adobe Systems, San Jose, CA) for labeling. The other two salamanders were also collected in Crawford County, Missouri in March; however, day and year of collection were not reported. These salamanders were previously fixed in formalin and preserved in 70% EtOH, and the entire urogenital tracts were prepared as described earlier.

The right urogenital tracts of salamanders fixed in McDowell's-Trump fixative were rinsed in phosphate buffered saline (PBS; pH 7.4) and subsequently postfixed in 2% osmium tetroxide in PBS (pH 7.4). Tissues were then rinsed with PBS (pH 7.4), dehydrated via a graded series of EtOH (70, 85, 95, and 100%), immersed in a 1:1 mixture of EtOH and propylene oxide, followed by pure propylene oxide, and subsequently embedded in Epon (EmBed 812, Electron Microscopy Science, Hatfield, PA) for ultrathin sectioning with a Leica EM UC6 ultramicrotome (Leica Microsystems, Wetzlar, Germany). Tissues were sectioned at 75–90 nm, placed on copper grids, and stained with uranyl acetate (15 min) and lead citrate (5 min). Grids were viewed with a JEOL JEM 100S transmission electron microscope (JEOL USA, Peabody, MA) and photographed with a L3C CCD digital camera (Scientific Instruments and Applications, Duluth, GA) or a Zeiss EM900 transmission electron microscope (Carl Zeiss, Berlin, West Germany) and photographed with a MegaView II digital camera (Soft Imagin System, Lakewood, CO). Images were subsequently uploaded into Adobe Creative Suite 5.5 for labeling.

## RESULTS

### Overview of the Testicular Sperm Ducts and Genital Kidney

The terminology used for delineating discrete regions of the testicular and genital kidney ducts is inconsistent and often confusing (see Table 1). Thus, in an effort to eliminate these problems, we utilize a lettering system to describe all regions of the testicular and genital kidney ducts. We tabulated the historical terminology with a lettering system to eliminate discrepancies.

Intratesticular ducts (regions a and $a^2$; see Table 1) transfer sperm from the testicular lobules and communicate the testis with more distal genital ducts. In *A. maculatum* the duct network is complex. One longitudinal testicular canal travels down the medial aspect of the testis (Fig. 1A–C, region a). A thin layer of fibroblasts and associated collagen fibers encompasses these ducts and all other ducts within the testis. Traveling longitudinally through the testes, transverse branches from the longitudinal testicular canal branch laterally and traverse deep into the testis (Fig. 1A,B,D, region $a^2$). Each transverse branch of the testis is surrounded by testicular lobules. Thus, it is these branches that immediately drain sperm from the testicular lobules.

The longitudinal testicular duct connects into what has been historically termed the vasa efferentia intratesticularly (region b; see Table 1) from the longitudinal testicular duct's medial aspect (Fig. 1B). This duct possesses a squamous epithe-

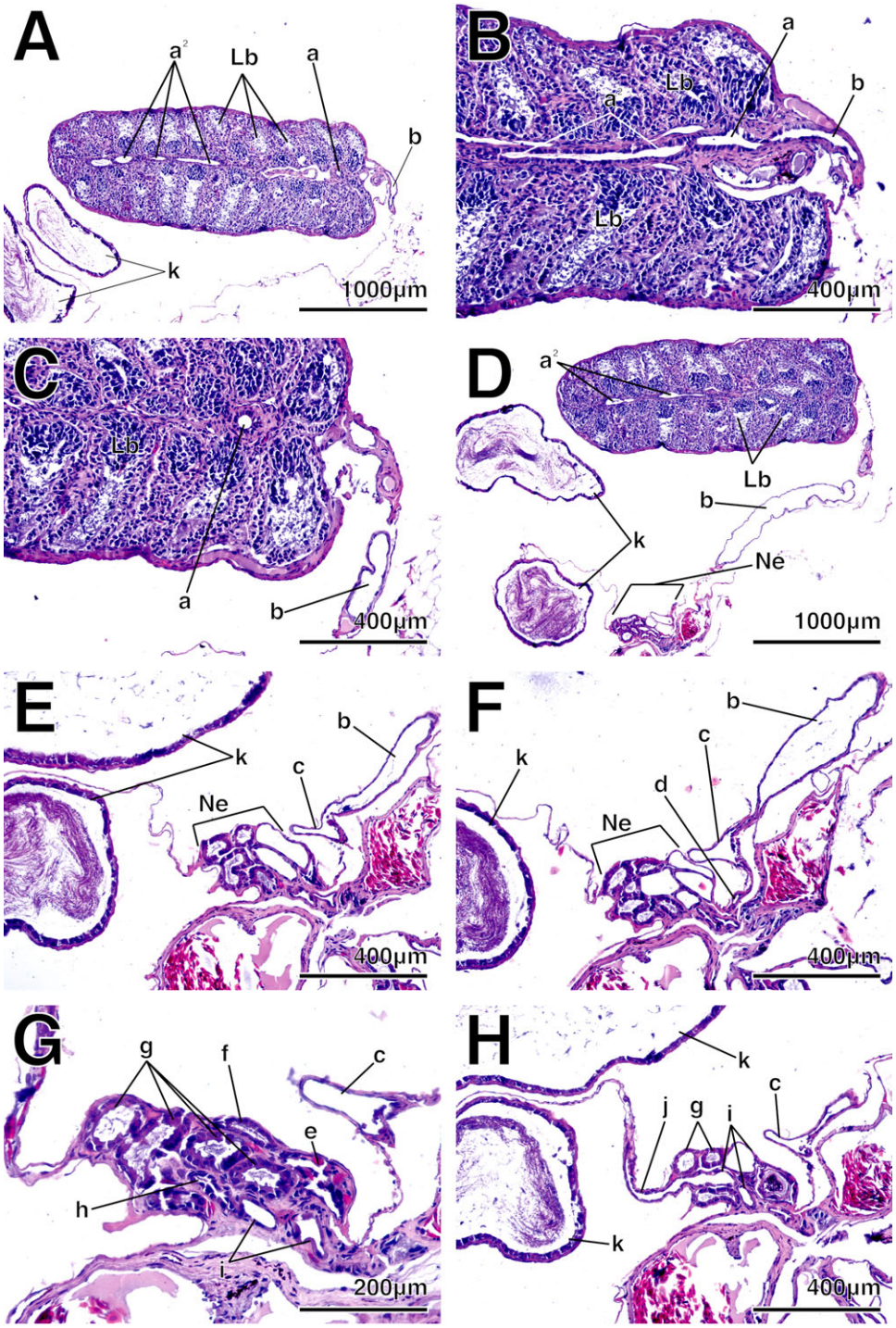


Fig. 1. Histology of the testicular and genital kidney ducts of *A. maculatum* (hematoxylin and eosin). **A**: Overview of the testis. **B:** High magnification of the lateral branches of the testicular ducts ($a^2$) communicating with the longitudinal branch of the testicular ducts (a), which in turn is communicating with what has historically been termed the vasa efferentia (b). **C:** High magnification of the longitudinal branch of the testicular ducts (a) and what has historically been termed the vasa efferentia (b) branching medially and dorsally away from the testis. **D:** Overview of what has historically been termed the vasa efferentia (b) reaching toward the genital kidney nephron (Ne), which lies, medial to the Wolffian duct (k). **E:** High magnification of what has historically been termed the vasa efferentia (b) emptying into what has often been termed the Bidder's duct (c). **F:** High magnification of what has historically been termed the afferent epididymal duct (d) branching from the Bidder's duct (c) and reaching toward the genital kidney nephron (Ne). **G:** High magnification of the different regions of the genital kidney nephron: renal corpuscle (e), neck segment (f), proximal convoluted tubule (g), intermediate segment (h), and distal convoluted tubule (i) of the genital kidney nephron. **H:** High magnification of the genital kidney collecting tubule (j) communicating the more proximal regions of the genital kidney nephron with the Wolffian duct (k). Lb, testicular lobules; Ne, nephron tubules of the genital kidney. Letters a–k correspond to letters in the first row of Table 1, which in-turn correspond to historical nomenclature; $a^2$ corresponds to lateral branches of the testicular ducts that have not previously been recognized in historical work and is this lacking from Table 1. [Color figure can be viewed in the online issue, which is available at wileyonlinelibrary.com.]

lium and a reduced lamina and serosa upon exiting the testis. This duct bends dorsally after traveling extratesticularly (Fig. 1B,C), extends laterally (Fig. 1D), and communicates with what has historically been termed the Bidder's duct (region c; see Table 1) immediately lateral to the postcava (Fig. 1E). This Bidder's duct (region c; see Table 1) travels longitudinally along the lateral aspect of the postcava in the entire genital region. The duct's squamous epithelium and highly reduced lamina and serosa appear identical to that of the historically termed vasa efferentia (region b; see Table 1). A small duct that historically is known as the afferent epididymal duct (region d; see Table 1) adjoins the Bidder's duct (region c; see Table 1) to the genital kidney nephron (Fig. 1F). This duct is histologically identical to the two previous regions (i.e., b and c).

The renal corpuscle (region e; see Table 1) marks the most proximal portion of the genital kidney nephron (Fig. 1G). A glomerulus resides within the capsular space (Fig. 1G). The capsule opens into a ciliated region with a cuboidal epithelium, which appears to be equivalent to the neck segment of the pelvic kidney (region f; see Table 1; Siegel et al., 2010). The neck opens into a ciliated region with an eosinophilic columnar epithelium that appears to be equivalent to the proximal convoluted tubule of the pelvic kidney (region g; see Table 1; Siegel et al., 2010). The neck region successively opens into an intermediate segment (Fig. 1G; region h; see Table 1) with a ciliated cuboidal epithelium, distal convoluted tubule (Fig. 1G; region i; see Table 1) with a nonciliated cuboidal epithelium, and finally a collecting tubule (Fig. 1H; region j; see Table 1) with a nonciliated cuboidal to columnar epithelium. The collecting tubule (region j) empties the contents of the testis, testicular ducts, and genital nephron into the Wolffian duct (Fig. 1H; region k; see Table 1).

A schematic is provided to illustrate the gross connections of the testicular and genital kidney ducts (Fig. 2).

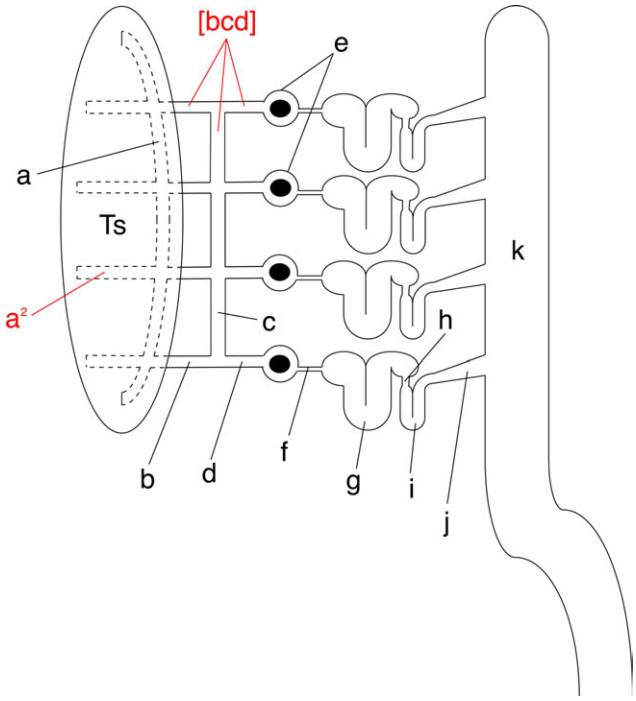


Fig. 2. Schematic of the testicular and genital kidney ducts of *A. maculatum*. Black lettering corresponds to letters in the first row of Table 1, which in-turn corresponds to historical nomenclature. Red lettering corresponds to regions that have been synthesized (i.e., vasa efferentia, Bidder's duct, and afferent epididymal duct; b–d) based on identical ultrastructure, or novel regions identified only in *A. maculatum* (i.e., lateral branches of the testicular ducts; $a^2$). Ts, testes. [Color figure can be viewed in the online issue, which is available at wileyonlinelibrary.com.]

## Ultrastructure

**a and $a^2$.** The epithelium of the testicular ducts (regions a and $a^2$; see Table 1 and Fig. 2) is simple cuboidal with centrally positioned nuclei that are irregularly shaped (Fig. 3A). Narrow and elongate mitochondria fill the spaces apical, lateral, and basal to the central heterochromatic nuclei (Fig. 3B–D). Glycogen granules are occasionally observed embedded in the mitochondria and pockets of glycogen granules fill lucent spaces in the cytoplasm (Fig. 3C,D). Aggregations of lipid droplets are scattered in the basal extremities of epithelial cells (Fig. 3D).

The apical membrane of the epithelial cells of the testicular canal is covered by a scattered array of short microvillus projections (Fig. 3B,C). The lateral membranes are interdigitating between epithelial cells forming labyrinthine intercellular canaliculi (Fig. 3C,D). The intercellular canaliculi are sealed from the lumen of the testicular canals by an apical tight junction adjacent to a single desmosome (Fig. 3C). No other junctional complexes are observed. The basal plasma membranes abut the basal lamina with no extensive membrane modifications (Fig. 3D).

The longitudinal branch of the testicular ducts (region a) is the only region where modifications to the epithelial cell composition occur. The region of the duct not immediately encompassed by testicular tissues possesses distended intercellular canaliculi that are similar to that of regions b–d (see Table 1 and Fig. 2). This epithelial variation represents the transition from the intratesticular ducts to the extratesticular ducts (see next section; Fig. 4). However, the cytoplasmic components are identical to that of the previously described intratesticular duct epithelium.

**b–d.** The historically termed vasa efferentia (region b; see Table 1; Fig. 2) and the afferent epididymal ducts (region d; see Table 1; Fig. 2) are encompassed by a thin visceral pleuroperitoneum

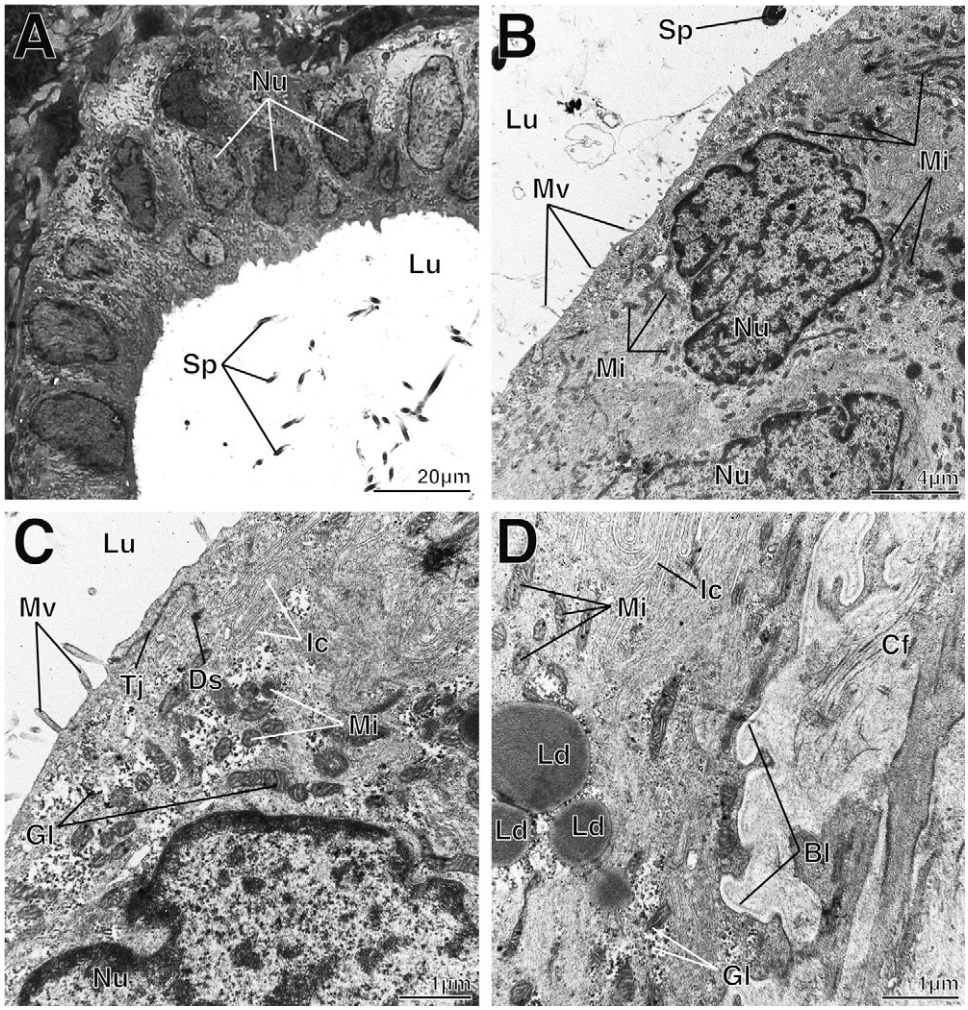


Fig. 3. Fine structure of what is traditionally termed the central testicular canal (region a), but also other unnamed testicular ducts (region $a^2$), of *A. maculatum*. **A:** Low magnification of region a and $a^2$ epithelial cells depicting the simple cuboidal/columnar epithelium (toluidine blue). **B:** Overview of a region a and $a^2$ epithelial cell depicting general cellular organization (uranyl acetate and lead citrate). **C:** High magnification of the apical and lateral membranes, and apical cytoplasmic contents of a region a and $a^2$ epithelial cell (uranyl acetate and lead citrate). **D:** High magnification of the basal membrane and basal cytoplasmic contents of a region a and $a^2$ epithelial cell (uranyl acetate and lead citrate). Bl, basal lamina; Cf, collagen fibers; Ds, desmosome; Gl, glycogen; Ic, intercellular canaliculi; Nu, nucleus; Ld, lipid droplets; Lu, lumen; Mi, mitochondria; Mv, microvilli; Sp, sperm; Tj, tight junction.

that is continuous with that of the testis and surrounds a deep layer of collagenous fibers (Fig. 4A). Fibroblasts are scattered sporadically among the collagen matrix (Fig. 4A). The epithelium of region b and d is simple squamous and is most easily identified by widened intercellular canaliculi (Fig. 4A–E). The large intercellular canaliculi are formed from lateral cytoplasmic projections (lamellae) that interdigitate between epithelial cells (Fig. 4B,C). While the majority of the lateral aspects of individual epithelial cells are not adjoined to adjacent cells, desmosomes are present sporadically along the lengths of the lateral membranes (Fig. 4C). The intercellular canaliculi are sealed from the lumen of the ducts by tight junctions apically and desmosomes immediately basal to the tight junctions (Fig. 4C). Basally, the intercellular canaliculi are not sealed where they abut the basal lamina. The basal plasma membrane of each epithelial cell abuts the basal lamina with no noticeable membrane modifications (Fig. 4D). The apical plasma membrane also has no discrete modifications other than occasional short microvilli and could most accurately be described as smooth (Fig. 4A,B,C,E).

The nuclei of the individual epithelial cells from regions b and d (see Table 1; Fig. 2) are centrally located, irregularly shaped, apically/basally flattened, dark, and heterochromatic (Fig. 4A,B,D). The cytoplasm surrounding the nuclei is dark due to a dense array of mitochondria filling the spaces apical, basal, and lateral to the nuclei (Fig. 4B,D,E). Between mitochondria the cytoplasm is diffuse and granular with small glycogen aggrega-

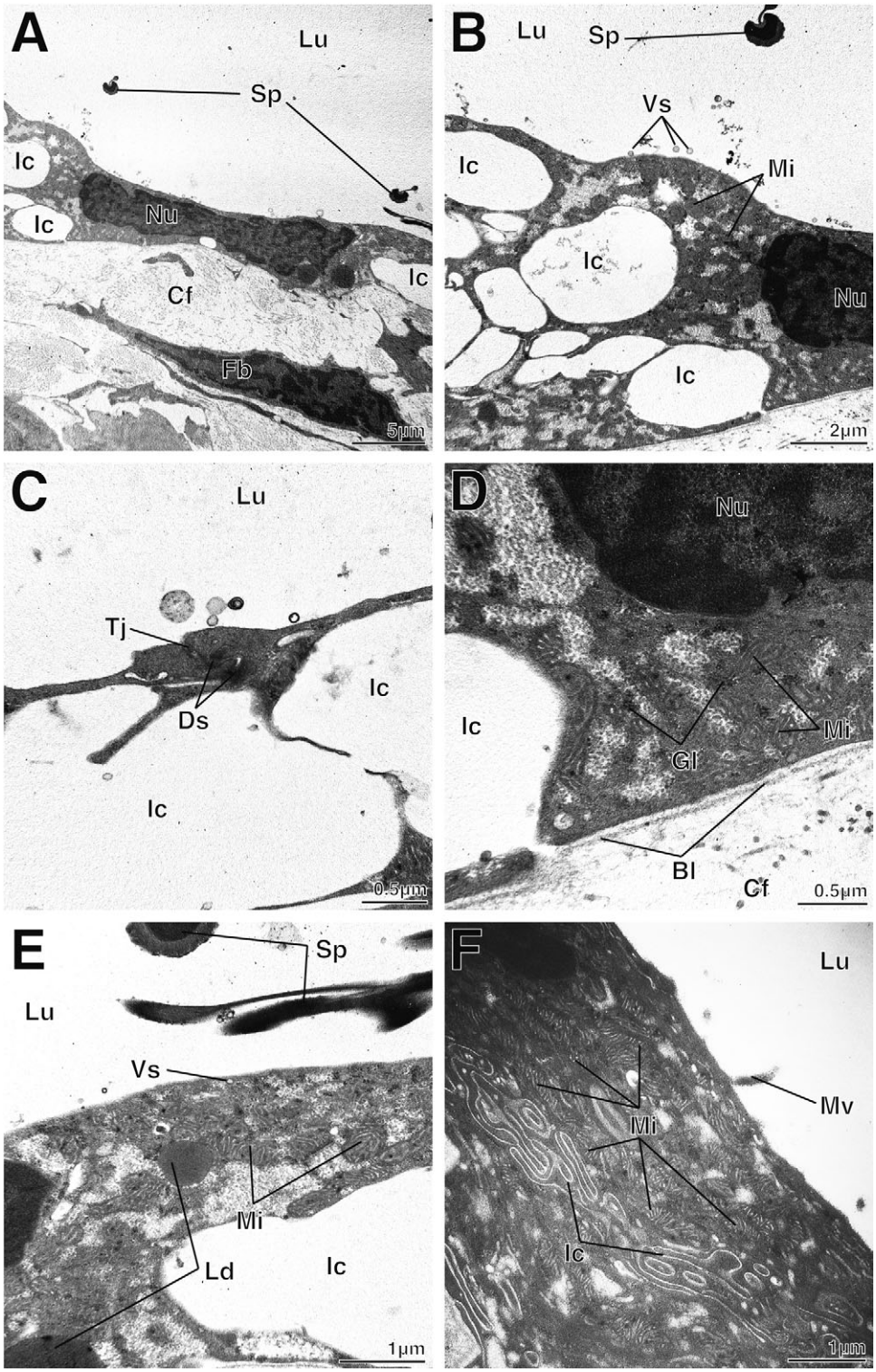


Fig. 4. Fine structure of what are traditionally termed the vasa efferentia, Bidder's duct, and afferent epididymal ducts (regions b–d) of *A. maculatum*. **A:** Overview of a region b–d epithelial cell depicting general cellular organization (uranyl acetate and lead citrate). **B:** High magnification of the apical and lateral membrane, and lateral cytoplasmic contents of a region b–d epithelial cell (uranyl acetate and lead citrate). **C:** High magnification of the junction between two epithelial cells in region b–d (uranyl acetate and lead citrate). **D:** High magnification of the basal membrane and basal cytoplasmic contents of a region b–d epithelial cell (uranyl acetate and lead citrate). **E:** High magnification of the apical cytoplasm of a region b–d epithelial cell (uranyl acetate and lead citrate). **F:** High magnification of the junction between two epithelial cells in region c where the region c tubule abuts the postcava (uranyl acetate and lead citrate). Bl, basal lamina; Cf, collagen fibers; Ds, desmosome; Fb, fibroblast; Gl, glycogen; Ic, intercellular canaliculi; Ld, lipid droplets; Lu, lumen; Mi, mitochondria; Mv, microvilli; Nu, nucleus; Sp, sperm; Tj, tight junction; Vs, vesicles.

tions (Fig. 4D). Within the cytoplasm lipid droplets can occasionally be found but do not appear to be restricted to any discrete position within individual cells (Fig. 4E). Immediately beneath the apical and basal membranes small lucent vesicles are occasionally observed within the cytoplasm (Fig. 4E); however, there is no evidence of fusion of these vesicles with the apical or basal membrane. Furthermore, similar vesicles are often found within the lumen juxtapositioned to the apical membrane, but likewise, there is no evidence of exocytosis of whole vesicles from the epithelial cells (Fig. 4B).

The historically termed Bidder's duct (region c; see Table 1; Fig. 2) represents a duct that is probably not distinct enough to warrant its own category. This duct shares an identical cytology with that of regions b and d (see Table 1; Fig. 2). However, the medial aspect of this duct that abuts the postcava possesses no noticeable distended regions of the intercellular canaliculi (Fig. 4F). In this portion of the duct, the canaliculi are narrow and labyrinthine due to numerous lateral membrane projections (Fig. 4F). This feature is prominent in region c (see Table 1; Fig. 2) throughout its entire length adjacent to the postcava.

**Genital Kidney Nephron (e, f, g, h, i, and j).** The historically termed afferent epididymal ducts (region d; see Table 1; Fig. 2) connect into the renal corpuscle of the epididymal nephron. The epithelium of the renal corpuscle is similar to that described in Siegel et al. (2010) from the pelvic kidney of male *A. maculatum* with a few exceptions. Markedly, the visceral epithelial cells of the renal corpuscle are greatly enlarged, feature a very dark cytoplasm, and have a quite large, heterochromatic, and irregular macronucleus (Fig. 5A). The darkness of the cytoplasm obscures the cytoplasmic contents; however, scant mitochondria (Fig. 5B), profiles of rough endoplasmic reticulum (Fig. 5B), and microfilament bundles (possibly centrioles; Fig. 5C) are observed in over-exposed higher magnification images. Vacuoles are also observed sporadically and are typically filled with an electron-dense material (Fig. 5C). Foot-like projections branch from the large visceral epithelial cells of the renal corpuscle forming filtration slits around the glomerular capillaries (Fig. 5C).

The portion of the genital kidney nephron immediately distal to the renal corpuscle is a ciliated neck region (region f; see Table 1; Fig. 2). This neck appears identical in terms of ultrastructure compared to that of the epithelium of the neck in the pelvic kidney (see Siegel et al., 2010). Distal to

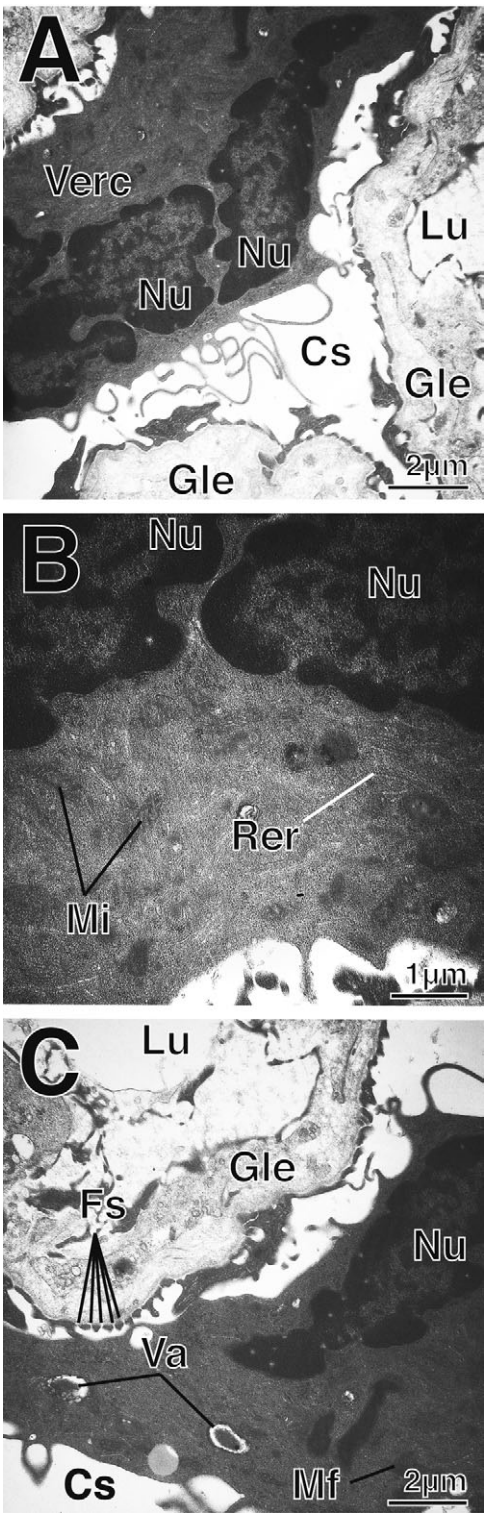


Fig. 5. Fine structure of the renal corpuscle (region e) from the genital kidney of *A. maculatum*. **A:** Overview of a typical visceral epithelial cell of the renal corpuscle depicting general cellular organization (uranyl acetate and lead citrate). **B:** High magnification of the cytoplasm of a typical visceral epithelial cell of the renal corpuscle (uranyl acetate and lead citrate). **C:** Overview of a typical visceral epithelial cell of the renal corpuscle highlighting the interaction with a glomerular capillary (uranyl acetate and lead citrate). Cs, capsular space; Fs, filtration slits; Gle, glomerular capillary epithelial cell; Lu, lumen; Mf, microfilaments; Mi, mitochondria; Nu, nucleus; Rer, rough endoplasmic reticulum; Verc, visceral epithelial cell of renal corpuscle.

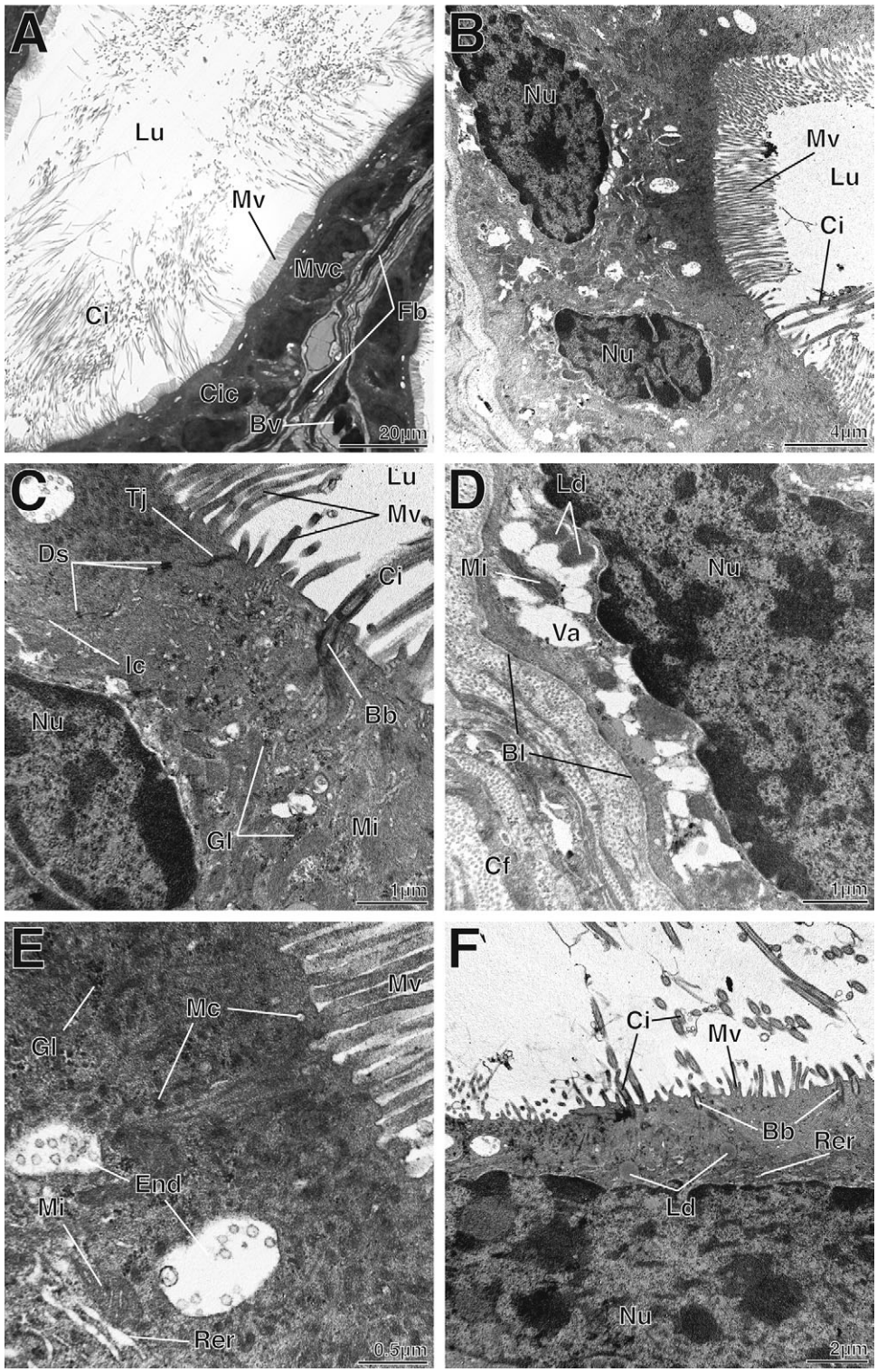


Fig. 6. Fine structure of the proximal convoluted tubule (region g) from the genital kidney of *A. maculatum*. **A:** Overview of a region g tubule depicting the alternating ciliated and nonciliated cells of this region (toluidine blue). **B:** Overview of a ciliated and nonciliated cell of region g depicting the general cellular organization of this region (uranyl acetate and lead citrate). **C:** High magnification of the apical membrane and lateral junctions of ciliated and nonciliated cells of region g (uranyl acetate and lead citrate). **D:** High magnification of the basal membrane and basal cytoplasmic contents of an epithelial cell from region g (uranyl acetate and lead citrate). **E:** High magnification of the apical membrane and apical cytoplasmic contents of a region g nonciliated cell (uranyl acetate and lead citrate). **F:** High magnification of the apical membrane and apical cytoplasmic contents of a region g ciliated cell (uranyl acetate and lead citrate). Bb, basal bodies; Bl, basal lamina; Bv, blood vessel; Cf, collagen fibers; Ds, desmosome; Fb, fibroblast; Ci, cilia; Cic, ciliated cell; End, endosomes; Gl, glycogen; Ld, lipid droplets; Lu, lumen; Mc, microvesicles; Mi, mitochondria; Mv, microvilli; Mvc, microvillus (nonciliated) cell; Nu, nucleus; Rer, rough endoplasmic reticulum; Tj, tight junction; Va, vacuole.

the neck the ciliated epithelium transitions into a columnar epithelium with alternating ciliated and nonciliated cells (Fig. 6A,B; region g; see Table 1; Fig. 2). Because of the dense microvillus brush-border of the nonciliated cells, we hypothesize that this region is homologous to the proximal convoluted tubule of the pelvic kidney (see Siegel et al., 2010). Discrete modifications of this epithelium, however, make it easily discernable from the proximal convoluted tubule of the pelvic kidney that are addressed in the discussion.

The nonciliated epithelial cells of the proximal convoluted tubule are completely covered apically by elongate microvilli (Fig. 6B). The lateral membranes of these epithelial cells are narrow, nonlabyrinthine, and sealed from the lumen of the epididymal duct by apical tight junctions with a series of desmosomes found immediately basal and along the entire length of the intercellular canaliculi (Fig. 6C). The basal plasma membrane is unmodified and abuts the basal lamina along its entire length with no folding (Fig. 6D). The apical cytoplasm is filled with endocytic microvesicles, larger endosome vacuoles, and profiles of rough endoplasmic reticula (Fig. 6E). Mitochondria and aggregations of glycogen granules are found intermixed with these vesicles and vacuoles (Fig. 6C,E). A heterochromatic and irregularly shaped nucleus fills the basal compartment of each nonciliated epithelial cell (Fig. 6B,C). In between the basal lamina and the nucleus, the cytoplasm is filled with large lucent vacuoles, mitochondria, aggregations of glycogen granules, and sparse profiles of rough endoplasmic reticula (Fig. 6D). Small lipid droplets are also occasionally observed basally (Fig. 6D).

Ciliated epithelial cells are similar in appearance to nonciliated cells; however, they possess 5–8 elongated cilia embedded through the apical membrane to basal bodies (Fig. 6F). Microvilli are also present on the apical surface of ciliated cells (Fig. 6F), but prominent endocytic activity is not present, as evidenced by the absence of endocytic vesicles and endosomes. Each ciliated cell also possesses abundant profiles of rough endoplasmic reticula (Fig. 6F), dense aggregations of glycogen and mitochondria (Fig. 6C), and the occasional lipid droplet in the apical region (Fig. 6F).

Distal to a short completely ciliated intermediate segment (with ciliated cells that match the descriptions of those found in Siegel et al., 2010; region h; see Table 1; Fig. 2), the proximal convoluted tubule transitions into a region that we hypothesize represents the homolog of the distal convoluted tubule (region i; see Table 1; Fig. 2) of the pelvic kidney (see Siegel et al., 2010). The basis for this hypothesis stems from the simple cuboidal nature of the epithelium (Fig. 7A) of this region and the cytoplasmic contents of each epithelial cell. However, differences between the two epithelia are noted and will be addressed further in the discussion.

Cells of the distal convoluted tubule possess small and scattered microvilli apically (Fig. 7B). The lateral epithelial cell membranes are labyrinthine in appearance due to the interdigitation of lateral membrane projections from each epithelial cell with its neighbor (Fig. 7B). Tight junctions seal the intercellular canaliculi apically followed by a single desmosome immediately basal (Fig. 7B). A labyrinthine basal plasma membrane is also observed due to invaginations of basal plasmalemma into the cell (Fig. 7C). The "foot" processes formed abut the basal lamina (Fig. 7C). The cytoplasm of the foot processes is filled with mitochondria oriented perpendicular to the basal lamina (Fig. 7C). Apically, the cytoplasm is devoid of organelles; however, just beneath the apical plasmalemma dark inclusions are prominent (Fig. 7B). The electron-dense inclusions do not appear to the membrane bound. We hypothesize that lipofuscin lateral to the central heterochromatic nucleus (Fig. 7D) is the source of these apical dense bodies.

The distal convoluted tubule transitions to a collecting tubule (region j; see Table 1; Fig. 2). The apical and basal surface of each collecting tubule epithelial cell is devoid of modification (i.e., no microvilli or foot processes, respectively; Fig. 8A–C). Lateral membrane projections result in labyrinthine intercellular canaliculi (Fig. 8A,B,D); however, unlike in the distal convoluted tubule, the intercellular canaliculi are distended (Fig. 8A,B,D). Tight junctions seal the intercellular canaliculi from the lumen apically (Fig. 8B), followed by a series of desmosomes that persist down to the basal lamina (Fig. 8C). The nuclei of the epithelial cells are found in a basal position and are heterochromatic. In terms of cytoplasmic contents, lipid droplets are common in the space between the basal membrane and nucleus (Fig. 8C), smooth and rough endoplasmic reticulum are abundant apical to the nucleus (Fig. 8B), mitochondria are dispersed throughout the cells (but more common apical to the nucleus; Fig. 8C,D), and dense bodies like those found in the distal convoluted tubule are found immediately beneath the apical membrane. Endosomes are also common in the apices of the epithelial cells (Fig. 8D) but are more common laterally where they appear to communicate with the intercellular canaliculi (Fig. 8D).

## DISCUSSION

### Nomenclature

Previous terminology employed for delineating regions of the epididymal complex was not based on tissue analysis, but more from a gross/mechanistic view (for review, see Williams et al., 1984). Here, we provide terminology that is based on historical precedence, tissue/cell structure, and homology. Williams et al. (1984) completed the most comprehensive comparative study of the

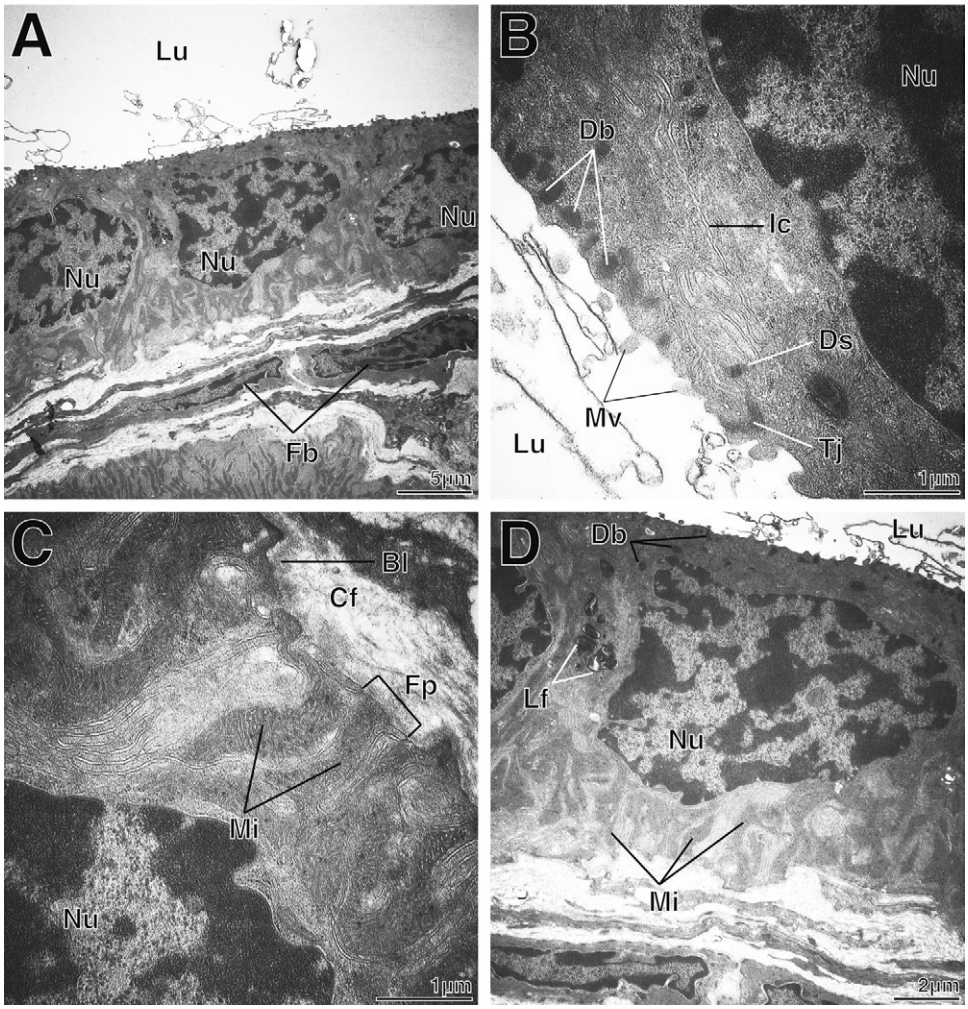


Fig. 7. Fine structure of the distal convoluted tubule (region i) from the genital kidney of *A. maculatum*. **A:** Overview of the epithelium from region i depicting the general cellular organization of this region (uranyl acetate and lead citrate). **B:** High magnification of the apical and lateral membranes, and apical cytoplasmic contents of a region i epithelial cell (uranyl acetate and lead citrate). **C:** High magnification of the basal membrane and basal cytoplasmic contents of a region i epithelial cell (uranyl acetate and lead citrate). **D:** Overview of a single region i epithelial cell depicting the general organization of cytoplasmic contents (uranyl acetate and lead citrate). Bl, basal lamina; Cf, collagen fibers; Db, dense bodies; Ds, desmosome; Fb, fibroblast; Fp, foot process; Ic, intercellular canaliculi; Lf, lipofuscin; Lu, lumen; Mi, mitochondria; Mv, microvilli; Nu, nucleus; Tj, tight junction.

epididymal complex in salamanders. Their diagram (see Fig. 3, Williams et al., 1984) and terminology used has been redrawn (Fig. 2) and tabulated (Table 1) in comparison with historical terminology. From Table 1, it is clear that inconsistencies have existed for over a century in the terminology of ducts connecting the testes to the mesonephric duct. The lettering system employed in this article will aid in future comparisons of the different regions of the sperm ducts and provide a terminology that represents a sound hypothesis of homology while maintaining historical precedence. In this way, future comparative studies of kidney regions within Caudata may use our more universally sound regional names or lettering system to remove confusing anatomical jargon and allow morphologists to better understand the evolution and morphology of the extratesticular and kidney ducts within salamanders.

From analysis of *A. maculatum*, it is clear also that a single longitudinal testicular duct (region a; see Table 1; for review, see Williams et al., 1984) is not the only type of testicular duct that can be found in the testis. In *A. maculatum* testes, lateral branches (region $a^2$; see Table 1) empty the contents of testicular lobules into a single longitudinal testicular duct. Thus, we utilize the term "intratesticular ducts" to represent the extent of ducts found within the testis. These ducts are ultrastructurally identical, and thus, we hypothesize that they are all of identical testicular origin. Subsequent authors should use appropriate directional adjectives to pinpoint what branch of the testicular ducts they are referring to in anatomical compari-

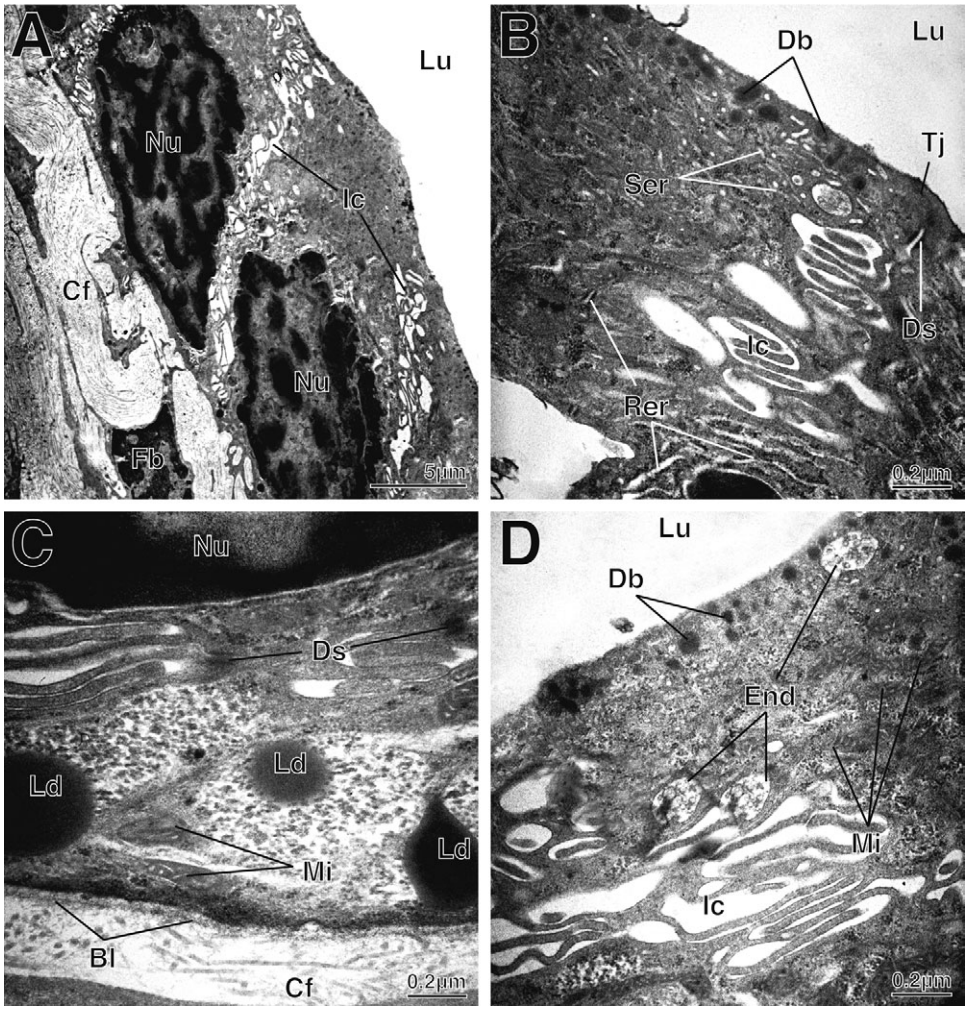


Fig. 8. Fine structure of the collecting tubule (region j) from the genital kidney of *A. maculatum*. **A:** Overview of the region j epithelium depicting the general organization of cells in this region (uranyl acetate and lead citrate). **B:** High magnification the apical and lateral membranes, and apical cytoplasmic contents of a region j epithelial cell (uranyl acetate and lead citrate). **C:** High magnification of the basal membrane and basal cytoplasmic contents of a region j epithelial cell (uranyl acetate and lead citrate). **D:** High magnification of the lateral membrane of a region j epithelial cells depicting the interaction of endosomes with the lateral intercellular canaliculi (uranyl acetate and lead citrate). Bl, basal lamina; Cf, collagen fibers; Db, dense bodies; Ds, desmosome; End, endosomes; Ic, intercellular canaliculi; Ld, lipid droplets; Lu, lumen; Mi, mitochondria; Nu, nucleus; Rer, rough endoplasmic reticulum; Ser, smooth endoplasmic reticulum; Tj, tight junction.

sons; that is, lateral branches. Other authors have also used the term "rete" to describe the testicular ducts (McCurdy, 1936; Rodgers and Risley, 1938; Rosenquist and Baker, 1967), but it is obvious that this terminology is not appropriate, because the testicular ducts are separated from the mesonephric duct by the mesonephros; and, thus, not of mesonephric duct origin like the rete testis in other vertebrates (Satoh, 1985).

The testicular ducts connect to ducts that we now term collectively as the vasa efferentia (regions b–d; see Table 1). These ducts originate intratesticularly and immediately exit the testes. These ducts are traditionally separated into three sets of ducts (see Table 1); however, they are all ultrastructurally identical and many authors believe that the longitudinal branch (region c; see Table 1) is formed from the anastomosis of several vasa efferentia, although the developmental evidence provided by McCurdy (1936) indicated that this is not the case. Some authors (Goodrich, 1930; Baker and Taylor, 1964) use the word "rete" to describe these ducts; however, this duct may not be homologous with what has been termed the rete in other vertebrates. The development of the rete testis appears to be inconsistent in amniote studies, and thus, we caution the usage of rete for regions b–d (see Table 1); that is, testicular chord origin (Brindak and Raïtsina, 1986), extratesticular origin (Wrobel, 2000), or mesonephric duct derived (although no definitive results of the rete origin were provided; Satoh, 1985). The only developmental study of these ducts in salamanders (*Ambystoma*) indicates that the vasa efferentia

develop from the coelomic mesothelium as a longitudinal cord of cells (the precursor of region c; see Table 1) ventro-medial to the genital kidney (McCurdy, 1936). Branches from this cord (precursors to region b and d; see Table 1) interact with the renal corpuscles of the genital kidney and the testicular ducts of the testes (McCurdy, 1936). However, convergent similarities of this duct with the rete testis in other vertebrates are intratesticular and extratesticular portions, the formation of a "net" (in most salamander taxa besides plethodontids and rhyacotritonids; Spengel, 1876; Williams et al., 1984; Siegel et al., 2012a), a squamous epithelium, nonciliated (similar to most reptiles; Sever, 2010), and labyrinthine intercellular canaliculi (for review, see Sever, 2010). It is apparent that separation of the nomenclature of these vasa efferentia tubules into three distinct ducts has confused comparisons in the past, as plethodontids typically only have one vas efferens (Spengel, 1876; Williams et al., 1984). Thus, no longitudinal duct (region c; see Table 1) is present. As the longitudinal duct historically acts as a demarcation between the historically termed vasa efferentia (region b; see Table 1) and the afferent epididymal ducts (region d; see Table 1), the absence of this longitudinal branch in plethodontids has resulted in the incorrect assumption that plethodontids have lost two regions of the testicular ducts (regions c and d; see Table 1) when in all likelihood, plethodontids just have a reduced number of vasa efferentia.

The vasa efferentia (regions b–d; see Table 1) connect to the nephrons of the genital portion of the kidney (regions e–j) in almost all taxa investigated (for review, see Williams et al., 1984); see Table 1 and Fig. 2). Many authors have synthesized the entirety of the genital kidney nephron regions into the efferent epididymal ducts (see Table 1). We find this terminology limiting and inaccurate, considering we abandoned the usage of the afferent epididymal ducts (region d; see Table 1). Furthermore, the term "epididymal" implies direct mesonephric duct origin (for review, see Rodríguez et al., 2001), which is inaccurate considering these tubules are nothing more than nephrons from the cranial portion of the mesonephros. This single term also limits accurate comparisons, as some salamander taxa have lost discrete regions of the nephron in the genital kidney (i.e., *Rhyacotriton*; Siegel et al., 2012a). Future investigators should take great care when describing the different regions of the genital kidney nephrons, as the reduction or loss of genital kidney nephron regions may be important diagnostic or synapomorphic characteristics. For example, plethodontids have apparently lost all regionality of the genital kidney nephron (Williams et al., 1984). However, the regions lost have not been described previously due to poor histological descriptions. Thus, we utilize the traditional terms for genital kidney nephron regions as those reported for the pelvic kidney, but add the term "genital kidney" to differentiate from the pelvic kidney nephrons (see Table 1).

The mesonephric duct (region k; see Table 1) has also been termed differently depending on taxa examined (see Table 1). We maintain the usage of Wolffian duct because of historical precedence, even though Spengel (1876) credits Leydig with the first description of this duct in salamanders. Some authors have used the term vas deferens because the collecting ducts of the pelvic kidney do not empty into the mesonephric duct in many taxa (for review, see Siegel et al., 2010). Thus, the term vas deferens was used to indicate that the mesonephric duct does not carry urine to the cloaca in some taxa. However, we find this inappropriate because this is not the case in all taxa (i.e., proteids and sirenids; Chase, 1923; Willett, 1965), and no evidence currently exists that confirms the complete separation of urine and reproductive materials in any taxa; for example, if the genital kidney nephrons are still capable of producing urine as hypothesized by Spengel (1876), no salamander would possess mesonephric ducts that carry only reproductive material.

## Morphology

We hypothesized that nephrons of the genital kidney in *A. maculatum* were modified from those of the pelvic kidney due to the function of the genital kidney nephrons as sperm transport conduits. From our ultrastructural analysis, we could not reject this hypothesis. Although the function of the genital kidney nephrons was not determined physiologically, the ultrastructure of the genital kidney nephron regions indicates altered function compared to the pelvic kidney nephrons.

The renal corpuscle of the genital kidney nephrons is ultrastructurally different to that of the renal corpuscle in the pelvic kidney of *A. maculatum* (Siegel et al., 2010). Whereas the renal corpuscle is similar in all other taxa examined from the pelvic kidney of salamanders (Sakai and Kawahara, 1983; Siegel et al., 2010) and other amphibians (Møbjerg et al., 1998, 2004), in the genital kidney the visceral epithelial cells are very large, with macronuclei, and extremely electron dense cytoplasms. Whether or not these structural differences result in decreased urine filtration are unknown; however, it is of note that unlike in the pelvic kidney renal corpuscles and nephrons that possess abundant luminal filtrate (Siegel et al., 2010), the genital kidney nephrons are devoid of such material throughout their entire length. For example, see Figures 4A, 5A, and 6E from Siegel et al. (2010) for micrographs of abundantly stained material in the lumen of different regions of the

pelvic kidney nephron. This material was not observed in the genital kidney nephrons.

The genital kidney proximal convoluted tubule is lined by epithelial cells with elongate cilia along its entire length. This is not true for the proximal convoluted tubule of the pelvic kidney where only the most proximal portion of the tubule possesses epithelial cells with cilia (i.e., at the junction with the ciliated neck segment; Siegel et al., 2010). The motility of these epithelial cilia may aid in the movement of immature sperm through the genital kidney nephrons, as sperm in salamanders do not reach maximum maturity until they reach the Wolffian ducts (McLaughlin and Humphries, 1978; Russell et al., 1981; Matsuda, 1986). However, this hypothesis also postulated by Becker (1856) for the ductuli efferentes of amniotes has fallen under scrutiny due to the lack of organized movement of the cilia of the ductuli efferentes epithelium. Thus, luminal fluid mixing (see Hess, 1998) is currently the hypothesis of choice (for review see Hess, 2001).

Spengel (1876) indicated that there was no reason that the genital kidney nephrons could not produce urine; that is, all the functional units of the nephron found in the pelvic region of the kidney are present in the genital kidney. However, if true, the capacity for reabsorption of water and solutes in the proximal convoluted tubule would be decreased in the genital kidney compared to the distal kidney based on our ultrastructural analysis. This is evident by the lack of modification (i.e., folding) of the basal plasma membrane of nonciliated proximal convoluted tubule epithelial cells in the genital kidney. The surface area of the basal plasma membrane of the proximal convoluted epithelial cells of the pelvic kidney is greatly expanded due to complex foldings (Siegel et al., 2010), which is hypothesized to increase the rapid exchange of solutes and water across the membrane (Maunsbach and Boulpaep, 1984). Even aquatic taxa that have decreased necessity for water reabsorption in the proximal convoluted tubule have folded basal plasma membranes in the pelvic portion of the kidney (Clothier et al., 1978; Sakai and Kawahara, 1983; Maunsbach and Boulpaep, 1984), although to a lesser extent than terrestrial taxa (Maunsbach and Boulpaep, 1984; Siegel et al., 2010). Interestingly, the apical membrane of the genital kidney proximal convoluted tubules forms a brush border like that in the pelvic kidney indicating increased surface area for transport. Whereas lysosomes are not found in the cytoplasm of the genital kidney proximal convoluted tubule epithelial cells like those found in the pelvic kidney (Clothier et al., 1978; Sakai and Kawahara, 1983; Maunsbach and Boulpaep, 1984; Siegel et al., 2010), endocytic vesicles and large endosomes are common, further supporting the transport of materials across the apical plasma membrane.

Convergence between sperm ducts is apparent when comparing the ductuli efferentes of amniotes to the genital kidney proximal convoluted tubules of *A. maculatum* and possibly all salamanders. We do not hypothesize that these ducts are homologous because the ducutli efferentes in amniotes (at least in mammals, but may not be the case in birds; see Budras and Meier, 1981) form from a secondary branch from mesonephric tubules (Wrobel, 2001), whereas in salamanders the sperm transport ducts are formed from the primary mesonephric tubules of the mesonephros. Both ducts communicate with ducts that associate directly with the testes (amniotes, rete; *A. maculatum*, vasa efferentia). Both ducts are highly ciliated and also possess evidence of absorption through the apical membrane of nonciliated cells (i.e., microvilli and endosomes/lysosomes; for review, see Sever, 2010). The only major difference is apocrine blebbing from the epithelial cells lining the ductuli efferentes in amniotes (for review, see Sever, 2010). No blebbing or secretion synthesis was noted in the genital kidney proximal convoluted tubules of *A. maculatum*, or in any other region of the genital kidney nephron. However, a seasonal sample is necessary to test the hypothesis that the genital kidney nephrons of salamanders produce no secretions (possibly for sperm sustaination), a hypothesis outside the scope of this investigation.

In *A. maculatum* the genital kidney distal convoluted tubule is markedly different from that of the pelvic kidney. In the pelvic kidney, the distal convoluted tubule is identified by an extensive increase in basal plasma membrane surface area (Siegel et al., 2010). The folding of the basal plasma membrane is so extensive that on the opposite side of folds, the membrane actually appears to contact itself (Siegel et al., 2010). This is also the case in other salamander taxa (Clothier et al., 1978; Hinton et al., 1982; Sakai and Kawahara, 1983; Stanton et al., 1984). Although folding is apparent in the genital kidney distal convoluted tubule in *A. maculatum*, the folding is not to the same degree as in the pelvic kidney, indicating a decreased degree of reabsorption in not only the proximal convoluted tubule, but the distal convoluted tubule as well. In all other taxa, mitochondria also fill the entirety of the cytoplasm of epithelial cells of the pelvic kidney distal convoluted tubules. In the genital kidney, mitochondria are only highly aggregated in the foot processes of the basal cytoplasm, whereas the apical cytoplasm is filled with dense bodies. These dense bodies are similar in structure and location to the "biconcave discs" observed in the nonciliated epithelial cells of the Wolffian ducts in *Rhyacotriton* (Zalisko and Larsen, 1988). No functional hypothesis has currently been provided for these electron dense cytoplasmic inclusions; however, these inclusions appear to originate from aggregates of lipofuscin

oriented in the lateral cytoplasm of the distal convoluted tubule epithelial cells.

The collecting tubule of the genital kidney is similar in ultrastructure to the pelvic kidney collecting tubules in other studies on salamanders (i.e., Hinton et al., 1982) and other amphibians (Møbjerg et al., 1998, 2004). This includes dilated intercellular canaliculi that possess extensive projections of lateral membrane extensions. However, in all other amphibians, the basal membrane is also dilated with projections. This is not the case in the genital kidney collecting tubule of *A. maculatum*, indicating a decreased capability of reabsorption across the basal plasma membrane. Electron dense bodies like those found in the distal convoluted tubule genital kidney nephron are also found in the collecting tubule. We found no evidence of intercalated cells ultrastructurally, a similar finding to the lack of intercalated cells in the collecting duct system of larval *A. mexicanum* (Haugan et al., 2010). Whereas the collecting tubule empties into a collecting duct that hypertrophies due to the synthesis of secretions during the mating season in the pelvic kidney of *A. maculatum* (Siegel et al., 2010), no such duct exists in the genital kidney nephrons, and thus, the collecting tubule communicates directly with the Wolffian duct. Functional implications of these findings are currently unknown.

In conclusion, we provide the first ultrastructural analysis of the epithelia of the testicular ducts and genital kidney nephrons of an amphibian. Although no physiological data are provided that indicates the lack of urine production/concentration in the genital kidney nephrons of *A. maculatum*, the capability of reabsorprtion of materials across the basal plasma membrane in the genital kidney nephron regions must be reduced due to structural constraints (i.e., decreased basal plasma membrane surface area). Increased cilia in the proximal convoluted tubule may aid in sperm passage through the genital kidney nephrons. Thus, we support our hypothesis and conclude that the genital kidney nephrons are modified compared to those of the pelvic kidney for the function of sperm transport.

## ACKNOWLEDGMENTS

The authors thank Arkansas State University, Saint Louis University, Southeast Missouri State University, Southeastern Louisiana University, and Wittenberg University for continued support of our research.

## LITERATURE CITED

Aranzábal MCU. 2003. The testes, spermatogenesis and male reproductive ducts. In: Sever DM, editor. Reproductive Biology and Phylogeny of Urodela. New Hampshire: Science Publishers, Inc. pp 183–202.

Aranzábal MCU. 2009. Spermatogenesis and male reproductive system in Amphibia-Urodela. In: Ogielska M, editor. Reproduction of Amphibians. New Hampshire: Science Publishers, Inc. pp 100–124.

Baker CL. 1965. The male urogenital system of the Salamandridae. J Tenn Acad Sci 40:1–5.

Baker CL, Taylor WW. 1964. The urogenital system of the male *Ambystoma*. J Tenn Acad Sci 39:1–9.

Becker O. 1856. Über Flimmerepithelium im Nebenhoden des Menschen. Wien Wchnschr 6:184.

Brindak OI, Raïtsina SS. 1986. Development of the rete testis in the prenatal ontogeny of rodents and effect of prolactin and thyrotropin on its cellular differentiation. Ontogenez 17:500–507.

Budras K-D, Meier U. 1981. The epididymis and its development in ratite birds (ostrich, emu, rhea). Anat Embryol 162:281–299.

Chase SW. 1923. The mesonephros and urogenital ducts of *Necturus maculosus*, Rafinesque. J Morphol 37:457–531.

Clothier R, Worley R, Balls M. 1978. The structure and ultrastructure of the renal tubule of the urodele amphibian, *Amphiuma means*. J Anat 127:491–504.

Goodrich ES. 1930. Studies on the Structure and Development of Vertebrates. New York, NY: The Macmillan Co.

Haugan BM, Halberg KA, Jespersen Å, Prehn LR, Møbjerg N. 2010. Functional characterization of the vertebrate primary ureter: Structure and ion transpoprt mechanisms of the pronephric duct in axolotl larvae (Amphibia). BMC Dev Biol 10:1–9.

Hess RA. 1998. Effects of environmental toxicants on the efferent ducts, epididymis and fertility. J Reprod Fertil Suppl 53:247–259.

Hess RA. 2001. The efferent ductules: Structure and function. In: Robaire B, Hinto BT, editors. The Epididymis: From Molecules to Clinical Practice. NY: Kluwer Academic/Plenum. pp 49–80.

Hinton DE, Stoner LC, Burg M, Trump BF. 1982. Heterogeneity in the distal nephron of the salamander (*Ambystoma tigrinum*): A correlated structure function study of isolated tubule segments. Anat Rec 204:21–32.

Jones RC. 2001. Evolution of the vertebrate epididymis. In: Robaire B, Hinton BT, editors. The Epididymis: From Molecules to Clinical Practice. New York, NY: Springer. pp 11–34.

Kiernan JA. 1990. Histological and Histochemical Methods: Theory and Practice. New York: Pergamon Press, Inc.

Matsuda M. 1986. Difference of fertilizing capacity between testicular sperm and vas deferens sperm in *Cynops pyrroghaster*. Gam Res 14:209–214.

Maunsbach AB, Boulpaep EL. 1984. Quantitative ultrastructure and functional correlates in proximal tubule of *Ambystoma* and *Necturus*. Am J Physiol-Renal 246:710–724.

McCurdy HM. 1936. Development of the sex organs in *Triturus torosus*. Am J Anat 47:367–403.

McLaughlin EW, Humphries AA Jr. 1978. The jelly envelopes and fertilization of eggs of the newt, *Notophthalmus viridescens*. J Morphol 158:73–90.

Møbjerg N, Laresen EH, Jaspersen Å. 1998. Morphology of the nephron in the mesonephros of *Bufo bufo* (Amphibia, Anura, Bufonidae). Acta Zool 79:31–51.

Møbjerg N, Jespersen Å, Wilkinson M. 2004. Morphology of the kidney in the west African caecilian, *Geotrypetes seraphini* (Amphibia, Gymnophiona, Caeciliidae). J Morphol 262:583–607.

Ratcliff MA Jr. 1965. The male urogenital system in *Cryptobranchus*. J Tenn Acad Sci 40:52–57.

Rodgers LT, Risley PL. 1938. Sexual differentiation of urogenital ducts of *Ambystoma tigrinum*. J Morphol 63:119–141.

Rodríguez CM, Kirby JL, Hinton BT, Robaire BHB. 2001. The development of the epididymis. In: Robaire B, Hinto BT, editors. The Epididymis: From Molecules to Clinical Practice. NY: Kluwer Academic/Plenum. pp 251–268.

Rosenquist JW, Baker CL. 1967. The urogenital system of the male *Necturus maculosus*. J Tenn Acad Sci 42:1–9.

Russell LD, Brandon RA, Zalisko EJ, Martan J. 1981. Spermatophores of the salamander *Ambystoma texanum*. Tissue Cell 13:609–621.

Sakai T, Kawahara K. 1983. The structure of the kidney of Japanese newts, *Triturus* (*Cynops*) *pyrrhogaster*. Anat Embryol 166:31–52.

Satoh M. 1985. The histogenesis of the gonad in rat embryos. J Anat 143:17–37.

Sever DM. 2010. Ultrastructure of the reproductive system of the black swamp snake (*Seminatrix pygaea*). VI. Anterior testicular ducts and their nomenclature. J Morphol 271:104–115.

Siegel DS, Sever DM, Aldridge RD. 2010. The pelvic kidney of male *Ambystoma maculatum* (Amphibia, Urodela, Ambystomatidae) with special reference to the sexual collecting ducts. J Morphol 271:1422–1439.

Siegel DS, Wilson ER, Aldridge RD. 2012a. The urogenital system of the male *Rhyacotriton* and the evolution of the male urogenital duct system in salamanders. J Tenn Acad Sci 87:11–27.

Siegel DS, Murray CM, Wilson ER, Puleo ER, True KA, Aldridge RD. 2012b. Sexual kidneys in the red-spotted newt (*Notophthalmus viridescens*). J Herpetol 46:136–144.

Spengel JW. 1876. Das urogenitalsystem der amphibien. Arb d Zool Zoot Inst Wuürzburg 3:1–114.

Stanton B, Biemesderfer D, Stetson D, Kashgarian M, Giebisch G. 1984. Cellular ultrastructure of *Amphiuma* distal nephron: Effects of exposure to potassium. Am J Physiol 247:204–216.

Willett JA. 1965. The male urogenital system in the Sirenidae. J Tenn Acad Sci 40:9–17.

Williams AA, Brandon RA, Martan J. 1984. Male genital ducts in the salamanders *Eurycea lucifuga* and *Eurycea longicauda*. Herpetologica 40:322–330.

Wrobel KH. 2000. Morphogenesis of the bovine rete testis: The intratesticular rete and its connection to the seminiferous tubules. Anat Embryol 202:475–490.

Wrobel KH. 2001. Morphogenesis of the bovine rete testis: Extratesticular rete, mesonephros, and establishment of the definitive urogenital junction. Anat Embryol 203:293–307.

Yamagiwa S. 1924. Das urognitalsystem der urodelen. J Fac Agric Hokkaido 15:37–82.

Zalisko EJ, Larsen JH Jr. 1988. Ultrastructure and histochemistry of the vas deferens of the salamander *Rhyacotriton olympicus*: Adaptations for sperm storage. Scanning Microsc 2:1089–1095.