Observations on the Sexual Segment of the Kidney of Snakes with Emphasis on Ultrastructure in the Yellow-Bellied Sea Snake, *Pelamis platurus*

DAVID M. SEVER,[1]* JUSTIN L. RHEUBERT,[1,2] JILLIAN GAUTREAUX,[1] TOREN G. HILL,[1] AND LAYLA R. FREEBORN[1]
[1]Department of Biological Sciences, Southeastern Louisiana University, Hammond, Louisiana
[2]Department of Biology, Saint Louis University, Saint Louis, Missouri

ABSTRACT

The sexual segment of the kidney (SSK) is an accessory sex structure in male lizards and snakes (Squamata). We describe histology of the SSK in 12 species of snakes, including one from the basal Scolecophidia, *Leptotyphlops dulcis*, and from the more advanced Alethinophidia, species from the Acrochordidae (*Acrochordus granulatus*), Homalopsidae (*Cerberus rynchops*), Uropeltidae (*Teretrurus sanguineus*), and eight species from the Elapidae, including six species of sea snakes. We also describe the ultrastructure of the SSK of the sea snake, *Pelamis platurus*. The SSK of *L. dulcis* does not include the ureter but does include distal convoluted tubules (DCTs) and collecting ducts. In all other snakes examined, the SSK is limited to the DCTs and does not differ in histology by any consistent character. We found apparently mature individuals of several species with inactive SSKs. Hypertrophied SSKs give positive reactions for protein secretions but variable reactions for carbohydrates. Ultrastructure of the SSK of *P. platurus* reveals nuclei situated medially in the epithelium and mature electron dense secretory vacuoles in other areas of the cytoplasm. Product release is apocrine. Junctional complexes only occur at the luminal border, and intercellular canaliculi become widened and are open basally. No cytologically unique characters occur in the SSK of *P. platurus*. The ancestral condition of the SSK in squamates is the presence of simple columnar epithelium specialized for secretion of a protein + carbohydrate product that matures and is released seasonally. Anat Rec, 00:000–000, 2012. ©2012 Wiley Periodicals, Inc.

Key words: squamata; sea snakes; sexual segment; histology; ultrastructure

The sexual segment of the kidney (SSK) is a modification of the kidney ducts in the Squamata (lizards + snakes) that is usually limited to males (Aldridge et al., 2011). The SSK was first described by Gampert (1866) in the snake *Natrix natrix* and since then studied in a variety of species (Saint Girons, 1972; Rheubert et al., 2011). Although the function is still unknown, the SSK in Squamata has been hypothesized to be involved with pheromone production (Volsøe, 1944), copulatory plug formation (Devine, 1975), sperm activation (Bishop, 1959; Cuellar, 1966), and/or seminal fluid production

Grant sponsor: National Science Foundation; Grant number: DEB-0809831.

Layla R. Freeborn is currently affiliated with Department of Ecology and Evolutionary Biology, Tulane University, New Orleans, LA 70118.

*Correspondence to: David M. Sever, Department of Biological Sciences, Southeastern Louisiana University, SLU 10736, Hammond, LA 70402. Fax: 985-549-3851. E-mail: dsever@selu.edu

Received 7 November 2011; Accepted 26 January 2012.
DOI 10.1002/ar.22435
Published online in Wiley Online Library (wileyonlinelibrary.com).

© 2012 WILEY PERIODICALS, INC.

(Prasad and Reddy, 1972). A SSK also occurs as a secondary sexual structure in male Gasterosteidae (stickleback fish: Courrier, 1922; Jakobsson et al., 1999), in which the secretion is involved in construction of foam nests, and some male Caudata (salamanders: Siegel et al., 2010), in which the function of the secretion is unknown. The modified portions of the kidney tubules are considered to be independently evolved in squamates, fish, and salamanders (Siegel et al., 2010).

Across taxa, the location of the SSK within the nephron varies. Within stickleback fishes, it is found within the ventral kidney (Courrier, 1922), and within salamanders, it is restricted to the collecting ducts (Siegel et al., 2010). Within the Squamata, the location of the SSK can include the intermediate segment, distal convoluted tubule (DCT), collecting duct, ureter (Ur), and combinations of the aforementioned (for review, see Rheubert et al., 2011). Through character optimization on a molecular phylogeny, Rheubert et al. (2011) proposed that the ancestral condition of the sexual segment includes the DCT, collecting duct, and Ur. Within snakes, this ancestral SSK location was reported in the Scolecophidia by Fox (1965), but in more advanced snakes (Alethinophidia), the SSK is restricted to the DCT (Aldridge et al., 2011).

Considerable work has been done on the histology of the SSK at the light microscopy level, with the most comprehensive study being that by Saint Girons (1972) who examined 73 species representing 21 families. Ultrastructural studies are fewer and limited to *Lacerta siccula* (Furieri and Lanzavecchia, 1959), *Cnemidophorus lemniscatus* (Del Conte and Tamayo, 1973), *N. natrix* (Kühnel and Krisch, 1974), *Podarcis taurica* (Gabri, 1983), *Seminatrix pygaea* (Sever et al., 2002), *Nerodia sipedon* (Krohmer, 2004), *Scincella lateralis* (Sever and Hopkins, 2005), *Agkistrodon piscivorus* (Sever et al., 2008; Siegel et al., 2009a), *Boiga irregularis* (Siegel et al., 2009b), and *Hemidactylus turcicus* (Rheubert et al., 2011).

In this article, we use a sample of snakes similar to that used in a recent study on histology and ultrastructure of the anterior testicular ducts of snakes (Sever and Freeborn, 2012). We include eight species from the Elapidae, a cosmopolitan group of some 350 venomous species with fixed front fangs and which includes terrestrial and marine forms (Burbrink and Crother, 2011). From the terrestrial subfamily Elapinae, we examined *Micrurus tener* and *Naja samarensis*. From the marine taxa, we examined a sea krait, *Laticauda colubrina* from the subfamily Laticaudinae and five species of "true" sea snakes from the subfamily Hydrophiinae. This taxonomy has been followed by most recent authors (e.g., Lukoschek and Keogh, 2006; Vitt and Caldwell, 2009; Burbrink and Crother, 2011). Sea kraits and true sea snakes, however, at various times have been placed in their own separate family, Hydrophiidae (Smith, 1926), and Pyron et al. (2011) recently reported that subfamilies of Elapidae do not form well-supported monophyletic groups and refused to recognize them.

We compare our findings on the SSK of elapids to other marine snakes *Acrochordus granulatus* (Acrochordidae) and *Cerberus rynchops* (Homalopsidae) and to the terrestrial snakes *Leptotyphlops dulcis* (Leptotyhlopidae) and *Teretrurus sanguineus* (Uropeltidae). The Leptotyphlopidae are generally considered one of the most basal groups of snakes (Burbrink and Crother, 2011). The Uropeltidae is in the clade Henophidia (Burbrink and Crother, 2011), a group of snakes that form the sister group of the most advanced snakes, the Caenophidia, which includes all other species studied herein except for *L. duclis*. Acrochordidae is the most basal family in the Caenophidia, and the Elapidae are considered one of the most recently derived groups (Burbrink and Crother, 2011). Thus, this study involves a wide range of snakes from the most basal to the most advanced. We hypothesize that the SSK will be found in all of these taxa, and any histological differences in the SSK will reflect phylogenetic relationships.

We also present the first observations on the ultrastructure of the sexual segment in a sea snake, using *Pelamis platurus*. All of the other squamates whose SSK has been studied with ultrastructure are terrestrial. Sea snakes are derived from terrestrial elapids (Burbrink and Crother, 2011), and we hypothesize that the cytology of the SSK will not be affected by adaptation of *P. platurus* to a marine environment.

MATERIALS AND METHODS

Species Utilized

Specimens of *P. platurus* were collected specifically for this study and were deposited in the vertebrate collections at Southeastern Louisiana University (SLU). The remaining specimens came from collections at the Field Museum, Chicago, IL (FMNH) and the University of Texas, Arlington (UTAR). Museum specimens had been fixed in 10% formalin and stored in 60% ethanol. Table 1 summarizes source, snout-vent length (SVL), collection date, and locality information. Detailed locality data are unknown for some specimens.

Collection and Tissue Preparation

Specimens of *P. platurus* were collected, 10 July 2009, from approximately 12-km south of Playa del Coco in Golfo de Papagayo, Guanacaste, Costa Rica. Individual snakes were collected in dip nets and placed in a large plastic storage container filled with sea water. Specimens were euthanized within 12 hr of capture by lethal injection (3–5 mL) of 10% sodium pentobarbital in 70% ethanol. This procedure was approved by the Institutional Animal Care and Use Committee of SLU, Hammond, Louisiana. After death, SVL was measured from the tip of the snout to the posterior end of the cloacal orifice. The left reproductive tract, consisting of the testis, kidney, and efferent ducts, was removed from each specimen and fixed in 10% neutral buffered formalin (NBF) for light microscopy. The right reproductive tracts were placed in Trump's fixative, 2.5% glutaraldehyde and 2.5% formaldehyde in 0.1 M sodium cacodylate buffer at pH 7.4 (Electron Microscopy Sciences, Hatfield, PA), for electron microscopy. All required permits for the collection, euthanasia, and dissection of *P. platurus* were obtained from the Ministerio del Ambiente y Energía of the Costa Rican government.

Tissues from museum specimens stored in 60% ethanol and tissues from *P. platurus* fixed in NBF were rinsed in deionized water, dehydrated through a series of ethanol (70%, 80%, 95%, and 100%), cleared in two changes of toluene, and placed in melted paraffin under

TABLE 1. Specimens utilized in this study

Family/species	Coll number	SVL (cm)	Date coll	Locality
Acrochordidae				
Acrochordus granulatus	FMNH 202783	60.0	20 September 1975	Bohol Islands, Philippines
	FMNH 202791	35.5	20 September 1975	Bohol Islands, Philippines
Elapidae: Elapinae				
Micrurus tener	UTAR 32601	46.6	24 June 1992	Valverde County, TX
	UTAR 36753	55.2	18 March 1958	Liberty County, TX
Naja samarensis	FMNH 53531	X	18 October 1946	Mindanao, Davao Province, Philippines
Elapidae: Hydrophiinae				
Aipysurus eydouxii	FMNH 199455	61.5	8 March 1975	Johore, Mersing Province, West Maylasia
	FMNH 201418	70.0	14 April 1975	
Ephalophis greyi	FMNH 212349	65.0	16 February 1980	Western Australia
Hydrophis lamberti	FMNH 202922	80.0	11 September 1975	Gigantes Islands, Philippines
	FMNH 202929	122.0	30 September 1975	Gigantes Islands, Philippines
Hydrophis ornatus	FMNH 257233	80.0	24 May 1998	Sabah, Maylasia
	FMNH 257236	84.0	24 May 1998	Sabah, Maylasia
Pelamis platurus	SLU 0132	49.1	10 July 2009	Guanacaste, Costa Rica
	SLU 0133	47.6	10 July 2009	Guanacaste, Costa Rica
	SLU 0135	52.9	10 July 2009	Guanacaste, Costa Rica
	SLU 0138	56.5	10 July 2009	Guanacaste, Costa Rica
Elapidae: Laticaudinae				
Laticauda colubrina	FMNH 202798	92.5	15 September 1975	Philippines
	FMNH 202801	99.5	11 September 1975	Philippines
Homalopsidae				
Cerberus rynchops	FMNH 202757	62.5	19 September 1975	Bohol Islands, Philippines
	FMNH 202761	52.2	19 September 1975	Bohol Islands, Philippines
Leptotyphlopidae				
Leptotyphlops dulcis	FMNH 40960	11.2	10 April 1943	McLennan County, TX
	FMNH 40961	10.8	10 April 1943	McLennan County, TX
Uropeltidae				
Teretrurus sanguineus	FMNH 265872	16.0	16 April 1972	India
	FMNH 265886	17.0	16 April 1972	India

X = missing data.

vacuum for a period of 24 hr. Then, tissues were embedded in paraffin blocks that were allowed to harden before 10 μm thick sections were cut with a rotary microtome (RMC Instruments, Tucson, AZ) and affixed to albuminized slides. Alternate slides from each specimen were stained with hematoxylin–eosin (general histology), bromphenol blue (BB, for proteins), and treated with the periodic acid-Schiff (PAS) procedure (for neutral carbohydrates) counterstained with alcian blue (AB) 8GX at pH 2.5 (for carboxylated glycosaminoglycans). Procedures followed Hayat (1993). A Leica DM2000 compound microscope was used for viewing slides, and photographs were taken with a Leica DF420 attached digital camera (Leica Microsystems, Wetzlar, Germany). Measurements of 10 diameters of the SSK and proximal convoluted tubules (PCTs) from a single slide from each specimen were done using the Live Measurement Module associated with the Leica Application Suite.

Tissues for transmission electron microscopy (TEM) were rinsed in deionized water, postfixed in 2% osmium tetroxide, dehydrated through a graded series of ethanol (same as light microscopy), cleared in propylene oxide, and embedded in epoxy resin (Embed 812; Electron Microscopy Sciences). Plastic sections were cut using a Reichert ultramicrotome (Reichert Microscope Services, Depew, NY) and DiATOME (Biel, Switzerland) diamond knives at 1 μm and 70 nm. Toluidine blue was used to stain 1-μm thick sections. Sections with 70-nm thickness were placed on uncoated 200 mesh copper grids (Electron Microscopy Sciences) and stained with uranyl acetate and lead citrate. Grids were viewed using a JEOL 100 transmission electron microscope (JEOL, Tokyo, Japan) and photographed using a L3C CCD digital camera (Scientific Instruments and Applications, Duluth, GA).

For scanning electron microscopy (SEM), fixation of tissues was the same as for TEM. Subsequently, the tissues were dehydrated using a series of graded ethanol solutions, critical point dried with a Denton DCP-1, and sputter coated with gold palladium using a Denton Desk IV (Denton Vacuum, Moorestown, NJ). Specimens were viewed and photographed using a Philips XL20 scanning electron microscope (Philips Electronics, Eindhoven, The Netherlands).

Mean tubule diameter (dia), standard deviations (SD), and an unpaired Student's *t*-test, which tested the null hypothesis mean SSK dia $\neq$ mean PCT dia, were computed for each set of means at http://www.physics.csbshu.edu/cgi-bin/stats/t-test_bulk_form.html. Pearson's correlation coefficient (r) was calculated using Microsoft Office Excel (Redmond, Washington). Illustrations of both light and electron micrographs were made with Adobe Photoshop 7.0 (Adobe Systems, San Francisco, CA).

RESULTS

Light Microscopy

Measurements of the mean diameters of SSKs and PCTs from each specimen are given in Table 2. The SSK

TABLE 2. Summary of histochemistry[a] and tubule diameter[b]

Species	Coll number	HE[c]	PAS	AB	BB	Dia SSK[d]	Dia PCT	*T*
Acrochordus granulatus	FMNH 202783	E	−−	−−	−−	64.1 ± 5.57*	40.3 ± 2.81	4.41
	FMNH 202791	B/E	+	−−	+/−−	59.2 ± 9.64*	45.4 ± 2.86	4.32
Micrurus tener	UTAR 32601	E	++	−−	++	44.0 ± 4.53	37.0 ± 5.45	3.10
	UTAR 36753	E	++	−−	++	70.5 ± 8.63	41.2 ± 4.50	9.53
Naja samarensis	FMNH 53531	E	++	−−	+	146.0 ± 14.9	36.1 ± 4.22	22.5
Aipysurus eydouxii	FMNH 199455	B/E	−−	−−	−−	133 ± 16.6	60.2 ± 6.84	12.7
	FMNH 201418	E	+	−−	++	224.0 ± 32.2	53.2 ± 7.36	16.3
Ephalophis greyi	FMNH 212349	B	−−	−−	−−	60.8 ± 5.16*	37.9 ± 5.64	9.50
Hydrophis lamberti	FMNH 202922	B	+	−−	+	99.3 ± 6.61	47.1 ± 5.63	19.0
	FMNH 202929	B	++	−−	X	85.3 ± 7.08	43.6 ± 2.44	17.6
Hydrophis ornatus	FMNH 257233	E	++	−−	++	87.7 ± 7.69	50.5 ± 5.22	12.6
	FMNH 257236	E	+	−−	++	67.4 ± 5.57	47.6 ± 3.39	9.62
Pelamis platurus	SLU 0132	B/E	++	−−	+	51.0 ± 2.71*	29.2 ± 1.98	20.6
	SLU 0133	B	++	−−	+	82.9 ± 5.40	31.3 ± 4.65	22.9
	SLU 0135	B	++	−−	+	56.2 ± 5.40	41.3 ± 4.30	6.83
Laticauda colubrina	FMNH 202798	E	+	−−	++	161.0 ± 16.5	45.4 ± 4.48	21.4
	FMNH 202801	E	++	−−	++	162.0 ± 19.8	51.1 ± 4.11	17.4
Cerberus rynchops	FMNH 202757	B	+	−−	+	59.5 ± 4.84*	40.2 ± 7.59	6.80
	FMNH 202761	E	++	++	+	97.5 ± 7.38	47.5 ± 7.82	14.7
Leptotyphlops dulcis	FMNH 40956	B	+	−−	+	78.8 ± 6.88	48.7 ± 5.79	10.6
	FMNH 40961	B	+	−−	+	105.0 ± 8.55	57.6 ± 5.59	14.8
Teretrurus sanguineus	FMNH 265872	E	−−	−−	++	117 ± 9.45	44.1 ± 5.04	21.6
	FMNH 265886	E	−−	−−	+	142 ± 10.7	43.2 ± 7.85	23.6

[a]−−, absent; +, weak; ++, strong; X, missing data.
[b]Tubule diameter is in μm ± 1 SD; $P < 0.001$ for all T values except UTAR 32601, $P < 0.01$.
[c]B, basophilic; E, eosinophilic.
[d]An asterisk indicates SSKs were not hypertrophied.

and PCT means for each specimen are significantly different from one another, even when the SSK is inactive, at $P < 0.001$ except for a *M. tener* (UTAR 32601) at $P < 0.01$.

Leptotyphlopidae

In the two specimens examined, the SSK consists of nonciliated, basophilic, columnar epithelium with basal nuclei and includes both the DCTs and the collecting ducts (Cd, Fig. 1). The SSK is easily distinguished from PCTs whose epithelial cells are eosinophilic and cuboidal and from the squamous epithelium of the Ur, as it joins the collecting tubules (Fig. 1A). The SSK is weakly BB+; the proximal tubules are more intensely BB+; and the Ur does not react with this stain (Fig. 1B). Furthermore, the SSK is weakly PAS+, whereas the proximal tubules and the Ur are AB+ (Fig. 1C,D).

Interestingly, the mean 105.0-μm SSK dia of a 10.8-cm SVL *L. dulcis* (FMNH 40961) is significantly larger than active SSKs in some much larger snakes with hypertrophied SSKs, including *M. tener* (46.6-cm SVL, 44.0-μm dia; 55.2-cm SVL, 70.5-μm dia), *C. rynchops* (52.2-cm SVL, 97.5-μm dia), *Hydrophis lamberti* (80.0-cm SVL, 99.3-μm dia; 122.0-cm SVL, 85.3-μm dia), *Hydrophis ornatus* (80.0-cm SVL, 87.7-μm dia; 84.0-cm SVL, 67.4-μm dia), and *P. platurus* (52.9-cm SVL, 56.2-μm dia; 47.6-cm SVL, 82.9-μm dia).

Other families

In other species, the SSK is limited to the DCTs. Histological sections of active glands are illustrated for *P. platurus* (Fig. 2), other species (Figs. 3–5), and specimens with inactive glands (Fig. 6).

In specimens with hypertrophied SSKs, the epithelium is nonciliated, simple columnar. The cytoplasm is eosinophilic (Fig. 3) except *P. platurus* (Fig. 2A) and *H. lamberti* (Fig. 3A) in which the cytoplasm is basophilic. Nuclei are basal, except for *P. platurus* in which the nuclei are medial (Fig. 2A). In most specimens, when the SSK is hypertrophied, the entire cytoplasm is filled with secretory granules, but in some specimens, secretory granules are limited to the apical half of the epithelium (Fig. 4D,F). The lumen may be conspicuous and either empty (e.g., Figs. 4B,D, 5D), contain a matrix formed from the secretory granules (Fig. 3C), or the hypertrophy of the SSK cytoplasm can reduce the lumen to a narrow slit (Figs. 3B,D, 5A). As with *L. dulcis*, one of the smaller species, *T. sanguineus* (16.0- to 17.0-cm SVL) possesses SSKs much larger in diameter (means of 117 and 142 μm) than several much larger snakes. The Pearson's correlation coefficient ($r = -0.0106$) between SVL and mean SSK diameter is not significant at any P level.

Reactions to PAS/AB and to BB are mixed (Table 2). Particularly, strong PAS+ reactions for neutral carbohydrates are shown by the SSK granules of *P. platurus* (Fig. 2B), *L. colubrina* (Fig. 4A), *H. ornatus* (Fig. 4B), *H. ornatus* (Fig. 4C), *M. tener* (Fig. 4D), and *N. samarensis* (Fig. 4E). All other specimens with active glands have at least a weak reaction to PAS except for *T. sanguineus*, in which epithelia of the SSKs of neither specimen show PAS+ reactions. The SSK epithelium of none of the species reacts only to AB for glycosaminoglycans, but the purple tint of the reaction for *C. rynchops* (Fig. 4F) indicates a positive reaction to both PAS and AB.

The strongest reactions with BB for proteins are seen in *L. colubrina* (Fig. 5A), *Aipysurus eydouxii* (Fig. 5B), *H. ornatus* (Fig. 5C), *M. tener* (Fig. 5D), and one specimen of *T. sanguineus* (FMNH 265872). Other specimens

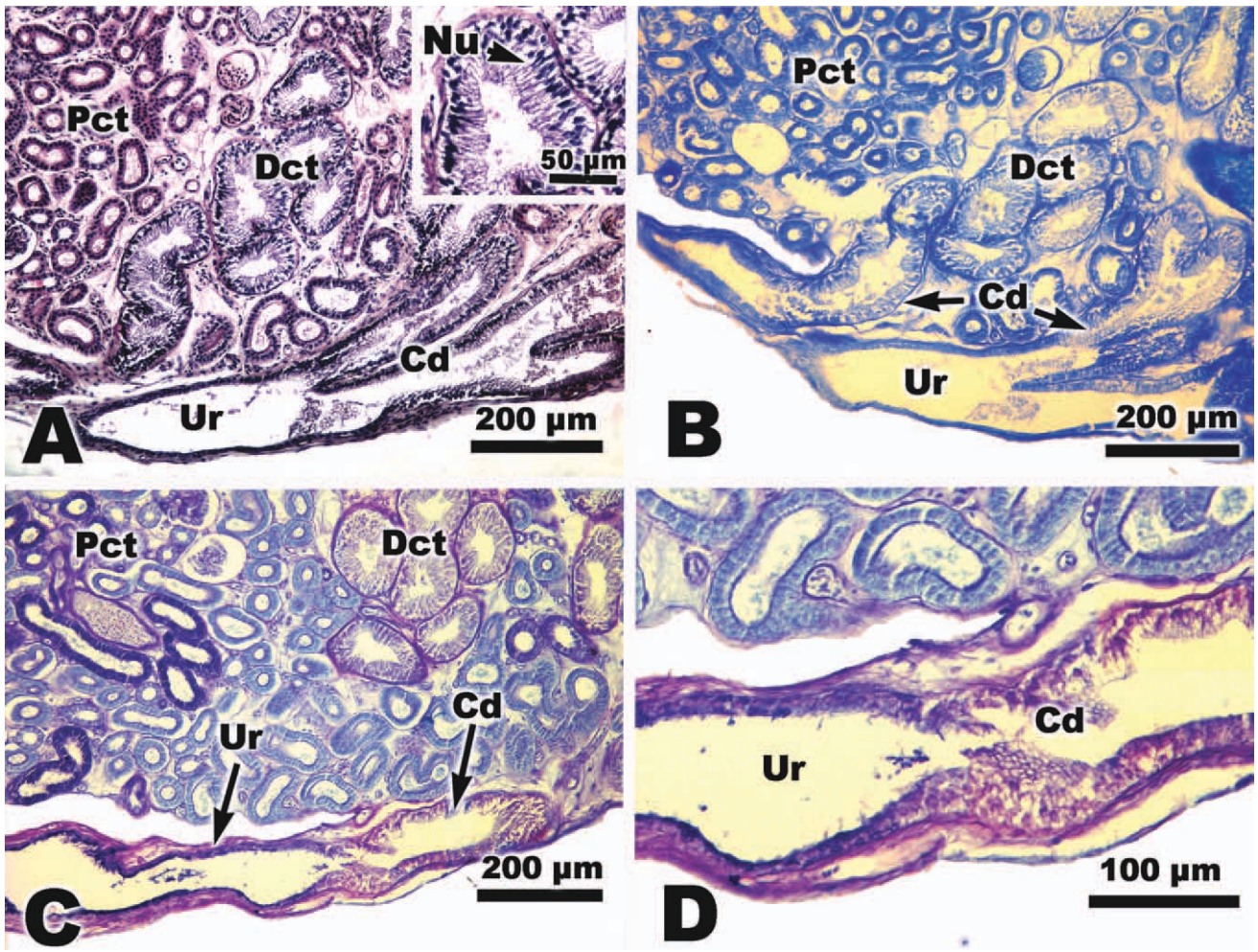

Fig. 1. Sagittal sections through the kidney of male *L. dulcis* (FMNH 40961, 10.8-cm SVL). (**A**) Hematoxylin–eosin. Inset shows higher magnification of a Dct and indicates the basal nuclei. (**B**) BB. (**C, D**) PAS procedure counterstained with AB at pH 2.5. Cd = collecting ducts; Dct = distal convoluted tubules; Pct = proximal convoluted tubules; Ur = ureter.

with hypertrophied glands show at least a weak response.

In several specimens, the SSK epithelium is not hypertrophied, including one *P. platurus* (SLU 132, Fig. 2D), both specimens of *A. granulatus* (Fig. 6A,B), one *C. rynchops* (Fig. 6C), and *Ephalophis greyi* (Fig. 6D). Difficulty exists in distinguishing PCTs and SSKs in hematoxylin–eosin stained sections, but the epithelia of the PCTs remain AB+ (Fig. 6A), as they are in kidneys with hypertrophied SSKs, so measurements were made on slides stained with AB/PAS. Even when not hypertrophied, however, SSKs are still significantly larger than PCTs (Table 2). Interestingly, the inactive SSKs of *C. rynchops* are basophilic (Fig. 6B), whereas in an active specimen, they are eosinophilic (Fig. 3B). Histochemical tests on inactive SSKs are weak or absent except for a *P. platurus* (SLU 0132) that has a strong PAS+ reaction (Table 2).

All *P. platurus* were collected the same day, they have active spermiation in the testes, and the one with an inactive SSK (SLU 132, 49.1-cm SVL) is larger in body size than one with active SSKs (SLU 0133, 47.6-cm SVL). Both the *A. granulatus* specimens also were collected on the same day, and testicular sections available from one of them (FMNH 202783) show the testis actively undergoing spermiation. The *C. rynchops* (FMNH 202757, 62.5-cm SVL) with inactive SSKs also has spermatids and sperm in its seminiferous tubules and was collected on the same day as a smaller specimen (FMNH 202761, 52.2-cm SVL) with hypertrophied SSK. The specimen of *E. greyi* (FMNH 212349) with inactive SSKs also has active spermiation in the testis. Of the above specimens, only the *P. platurus* have sperm in their proximal efferent ducts.

Ultrastructure of *P. platurus*

SEM analysis of the kidney of *P. platurus* (SLU 133) shows parallel cords of SSK tubules that are easily distinguished from adjacent PCTs by their greater

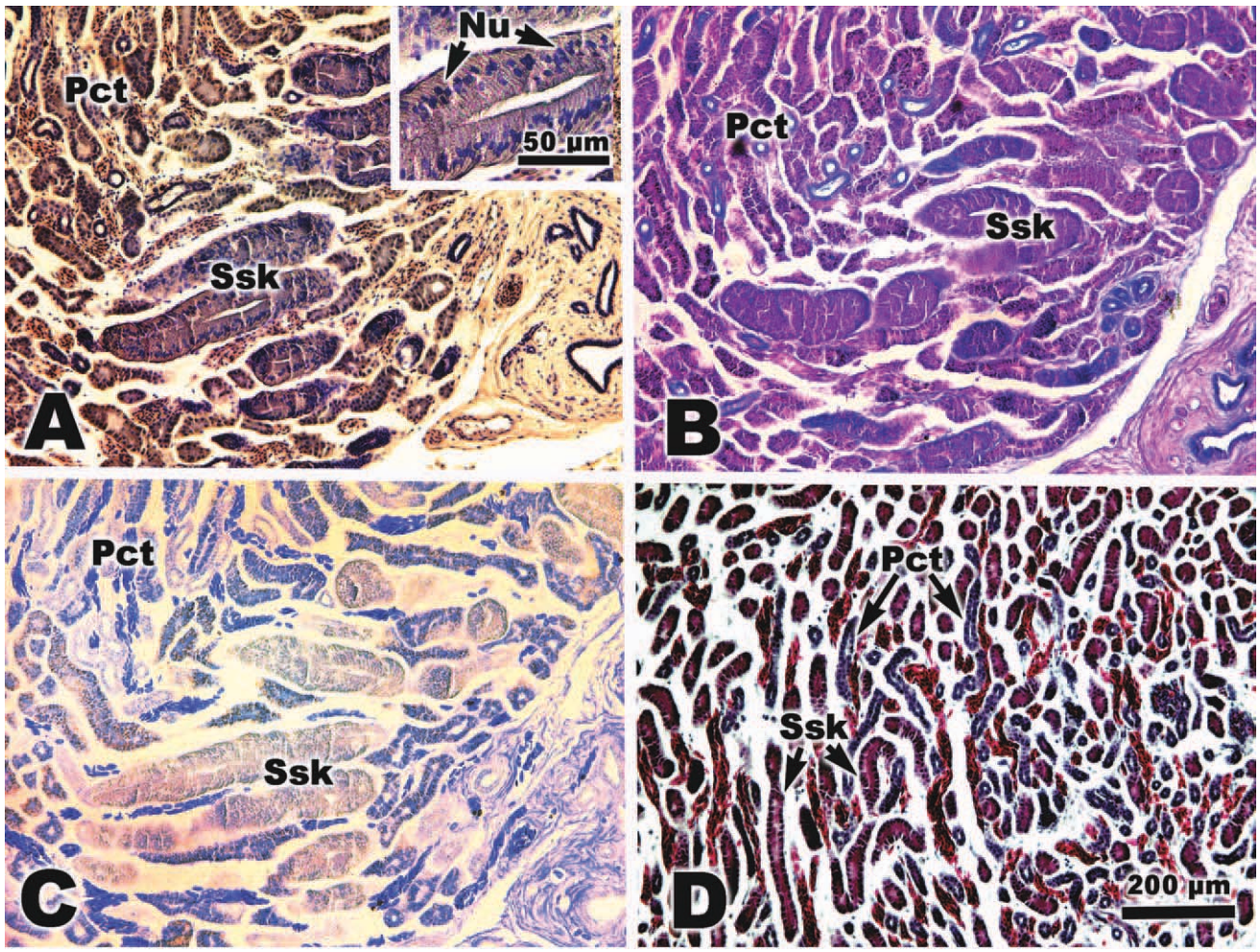

Fig. 2. Transverse sections through the kidney of male *P. platurus*. (**A–C**) SLU 133, 47.6-cm SVL showing staining reactions with (**A**) hematoxylin–eosin, inset shows higher magnification of a SSK and indicates the medial nuclei. (**B**) PAS procedure counterstained with AB at pH 2.5 (**C**) BB. (**D**) SLU 132, 49.1-cm SVL, showing inactive kidney tubules treated with the PAS procedure counterstained with AB at pH 2.5. Pct = proximal convoluted tubules; Ssk = sexual segment of the kidney.

diameters (Fig. 7A). Oval secretory vacuoles are conspicuous throughout the entire cytoplasm (Fig. 7B). The secretory vacuoles appear to pass through the apical cytoplasm intact, an apocrine process, and subsequently break down with other secretory vacuoles to form a matrix in the lumen (Malu, Fig. 7C).

The TEM observations were made on specimens SLU 133 and SLU 138, and both are the same in cytology. Secretory vacuoles are abundant in the entire perinuclear cytoplasm, and the occurrence of numerous secretory vacuoles infranuclearly results in a more medial location of the nucleus in the columnar epithelium (Fig. 8A). In overview, the intercellular canaliculi are narrow apically and widen toward the base of the tubule (Ic, Fig. 8A). The outer fibrous sheath is thin, and fibroblasts are limited to a single layer adjacent to the tubules (Fig. 8A). All of the secretory vacuoles in these specimens collected in June are mature, uniformly electron dense, and 0.5- to 1.5-µm dia depending on the plane of section (Fig. 8B). The only conspicuous organelles are clusters of rough endoplasmic reticulum in areas between the secretory vacuoles (Rer, Fig. 8B).

As noted above, SEM indicated an apocrine mode of product release, and TEM confirms the occurrence of dense secretory vacuoles protruding into the lumen at the apex of the epithelial cells (Fig. 9A), but no solid granules occur in the lumina of our TEM sections. The only junctional complexes noted between epithelial cells are a tight junction (zonula occludens) followed by a zonula adherens at the luminal end (Fig. 9B). As mentioned earlier, the intercellular canaliculi widen basally, and we observed intercellular canaliculi from adjacent cells joining to form intercellular spaces (Fig. 9C). Inferior to these spaces, the intercellular canaliculi have interdigitating lamellae (Fig. 9D). The terminal ends of the canaliculi lack junctional complexes and open into a

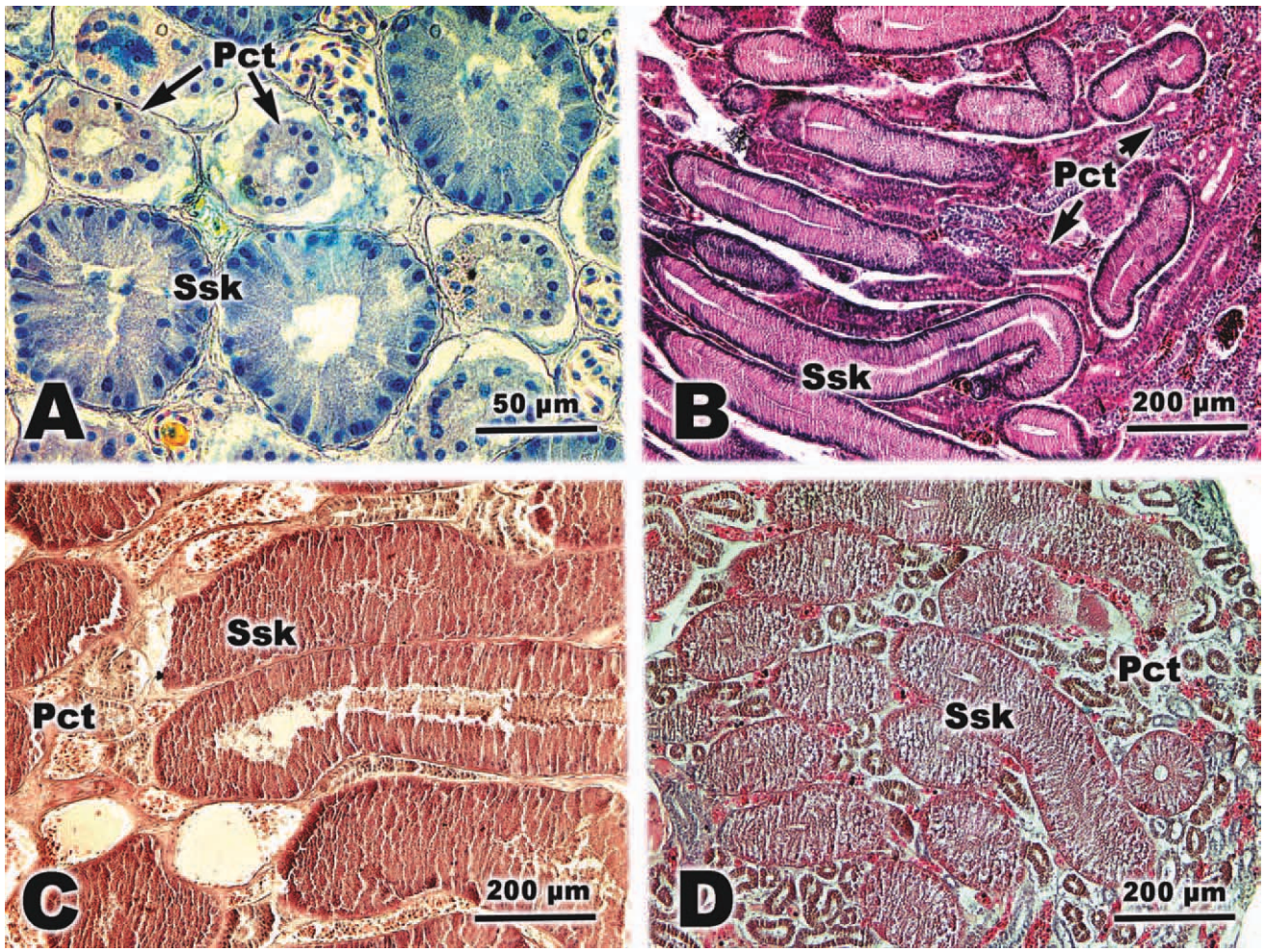

Fig. 3. Staining reactions of kidney tubules with hematoxylin–eosin. (**A**) *H. lamberti*, FMNH 202922, 80.0-cm SVL. (**B**) *C. rynchops*, FMNH 202761, 52.2-cm SVL. (**C**) *A. eydouxii*, FMNH 201418, 70.0-cm SVL. (**D**) *T. sanguineus*, FMNH 265886, 17-cm SVL. Pct = proximal convoluted tubules; Ssk = sexual segment of the kidney.

narrow gap (lamina lucida) adjacent to the basal lamina (Fig. 9D, inset arrow).

DISCUSSION

L. dulcis of the family Leptotyphlopidae represents one of the three families of Scolecophidia, widely considered the most basal group of snakes (Burbrink and Crother, 2011; Scanlon and Lee, 2011). Fox (1965) reported that *L. dulcis* and *L. humilis* as well as *Typhlops vermicularis* and *T. simoni* from another scolecophidian family, Typhlopidae, differ from more advanced snakes, including the collecting duct and Ur in the SSK. We agree that the collecting ducts should be included in the SSK of *L. dulcis*, because they have hypertrophied epithelium and have secretory activity like that of the DCTs. The Ur, however, from its beginning at the junction of the collecting ducts has low epithelium and, unlike the SSK, is AB+ (Fig. 1D). In lizards in which the Ur is considered part of the SSK, for example, *S. lateralis* (Sever and Hopkins, 2005), the Ur epithelium is hypertrophied and stains positively for proteins and neutral carbohydrates. The status of this character needs re-evaluation in other scolecophidians.

A muscular sheath has been reported around the SSK in another scolecophidian (*T. vermicularis* by Fox (1965). The SSK in our specimens of *L. dulcis*, like those examined by Fox (1965), are similar to advanced snakes in possessing just a thin collagenous sheath around the kidney tubules.

Using light microscopy, the SSK of specimens examined from the Acrochordidae, Elapidae, Homalopsidae, Hydrophiidae, and Uropeltidae is limited to the DCTs and cannot be distinguished at this level among these species by any consistent character. Also, the SSK of these snakes is similar to literature descriptions for species from the Boidae, Viperidae, Natricidae, and Colubridae (Saint Girons, 1972; Sever et al., 2002, 2008).

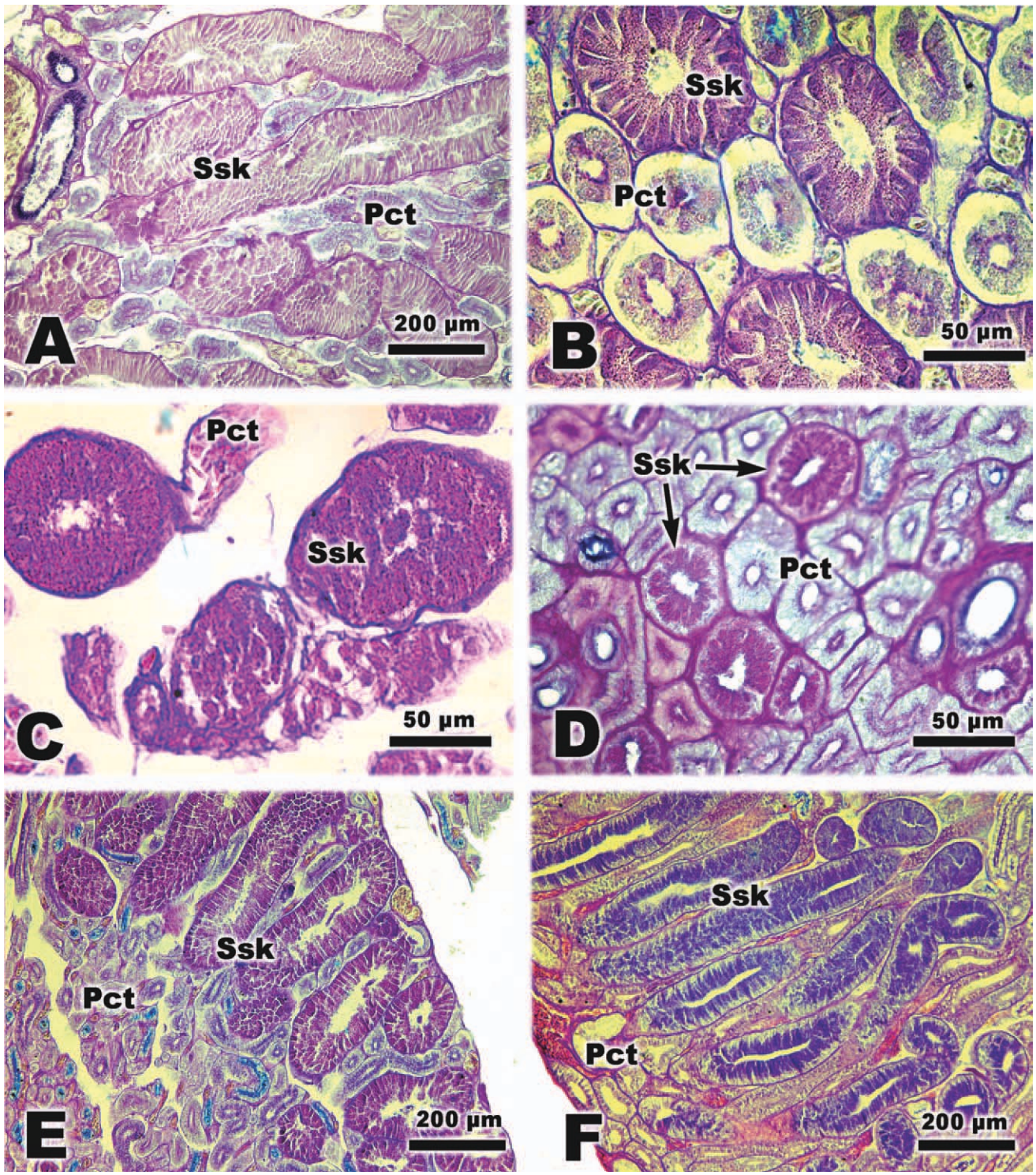

Fig. 4. Treatment of sections of kidney tubules treated with the PAS procedure counterstained with AB at pH 2.5. (**A**) *L. colubrina*, FMNH 202801, 99.5-cm SVL. (**B**) *H. lamberti*, FMNH 202929, 122.0-cm SVL. (**C**) *H. ornatus*, FMNH 257233, 80.0-cm SVL. (**D**) *M. tener*, UTAR 32601, 46.6-cm SVL. (**E**) *N. samarensis*, FMNH 53531. (**F**) *C. rynchops*, FMNH 202761, 52.2-cm SVL. Pct = proximal convoluted tubules; Ssk = sexual segment of the kidney.

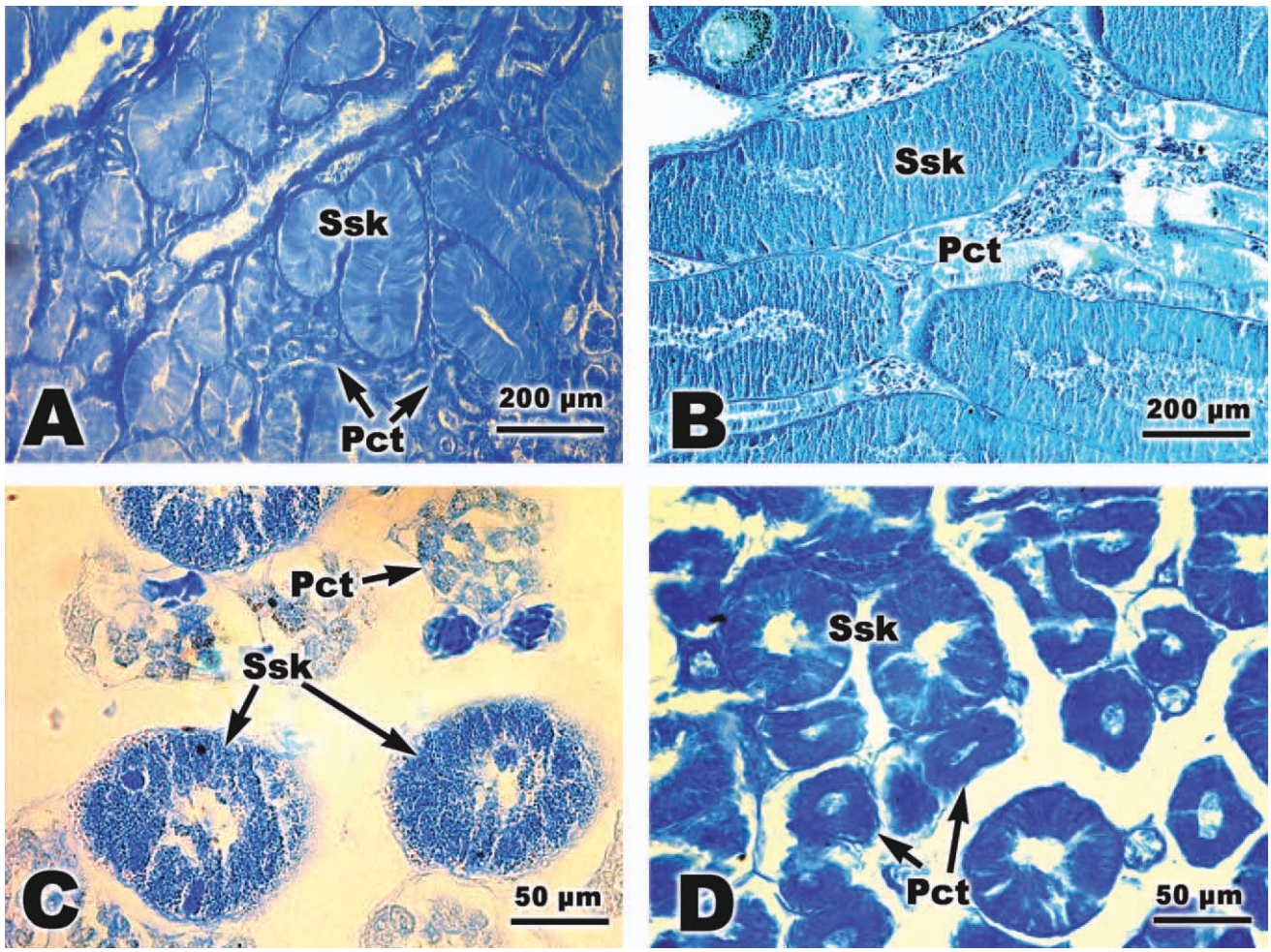

Fig. 5. Staining reactions of kidney tubules with BB. (**A**) *L. colubrina*, FMNH 202798, 92.5-cm SVL. (**B**) *A. eydouxii*, FMNH 201418, 70.0-cm SVL. (**C**) *H. ornatus*, FMNH 257236, 84.0-cm SVL. (**D**) *M. tener*, UTAR 32601, 46.6-cm SVL. Pct = proximal convoluted tubules; Ssk = sexual segment of the kidney.

Saint Girons (1972: 264) in his observations on 73 species of squamates found that the SSK secretory product "is always very rich in proteins and without acid mucins" but variable in the PAS reaction to neutral carbohydrates. We found a BB+ test for proteins in all species with hypertrophied glands, but the response was weak in some species (*C. rynchops*, *H. lamberti*, *P. platurus*, *L. dulcis*, and *T. sanguineus*). The SSK epithelium of one species, *C. rynchops*, shows a AB+ response for acid mucins (primarily carboxylated glycosaminoglycans) as well as being PAS+ for neutral carbohydrates.

The species studied by Saint Girons (1972) were one sea snake, *L. colubrina*, five elapids, and six homalopsids. Table 1 in Saint Girons (1972) indicates that the epithelia of the SSKs of *L. colubrina* did not react with PAS, and the average diameter of hypertrophied SSKs was 160 µm. Our specimens had SSKs similar in mean diameter (161–162 µm), but their epithelia gave weak (FMNH 202798) to strong (FMNH 202801) PAS+ reactions.

The elapids examined by Saint Girons (1972) had hypertrophied SSKs 145 µm (*Denisonia signata*) to 190 µm (*Naja naja*, the only species in this genus he examined) in mean diameter, and the epithelia of the SSKs were all negative with PAS except *N. naja*, which gave a weak response. Our *M. tener* had the smallest active SSKs of any species examined (44.0–59.2 µm), but the SSKs are strongly PAS+ like the much larger SSKs (146.0 µm) of our *N. samarensis*.

The homalopsids that Saint Girons (1972) studied included four species of *Enhydris*, *Erpeton tentaculatum*, and *Homalopsis buccata*. They had hypertrophied SSKs ranging from 88 µm (*Enhydris enhydris*) to 155 µm (*E. tentaculatum*). The SSK epithelia of all the homalospids examined by Saint Girons (1973) gave weak PAS+ responses. Our homalopsid was *C. rynchops*, which, as mentioned previously, has strong PAS+ and AB+ reactions but a weak response for proteins.

As reported by Saint Girons (1972: 264), we found that the diameter of hypertrophied SSKs is "independent" of the size of the specimen. He believed, however,

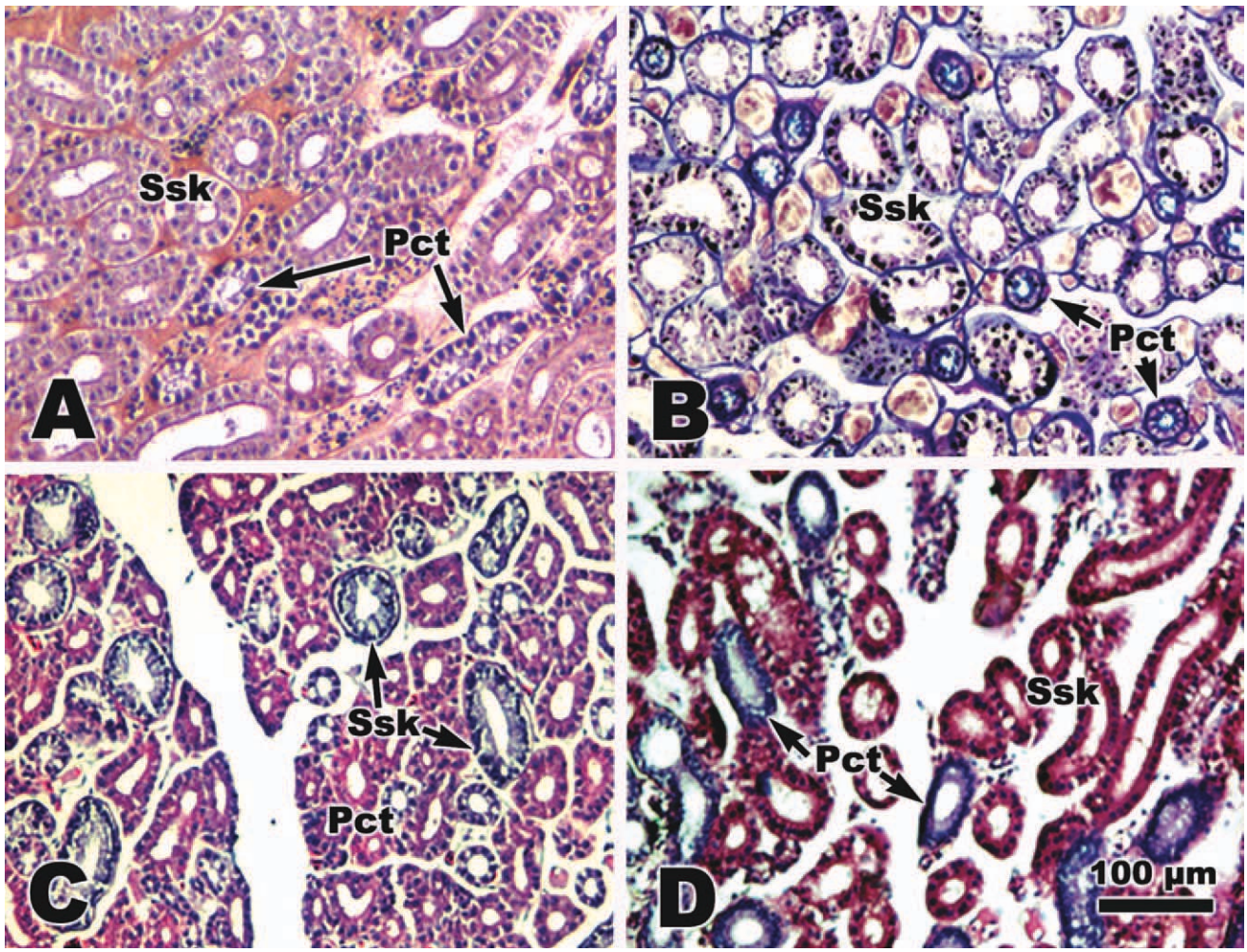

Fig. 6. Inactive SSK. (**A**, **C**) Stained with hematoxylin–eosin and (**B**, **D**) treated with the PAS procedure counterstained with AB at pH 2.5. (A) *A. granulatus*, FMNH 202791, 60.0-cm SVL. (B) *A. granulatus*, FMNH 202783, 35.5-cm SVL. (C) *C. rynchops*, FMNH 202757, 62.5-cm SVL. (D) *E. greyi*, FMNH 212349, 65.0-cm SVL. Pct = proximal convoluted tubules; Ssk = sexual segment of the kidney.

that the diameters might have systematic value, although this is not clear from his data.

Saint Girons (1972) also found, as we did, apparently mature individuals of various species with inactive SSKs as determined by reduction of tubule diameter and secretory activity. Saint Girons (1972) noted that differences in hypertrophy of the sexual segment occur within the same subfamily and same genus of snakes. The literature contains numerous observations that snakes undergo less seasonal variation in SSK hypertrophy than lizards (reviewed by Aldridge et al., 2011). Our findings and the results of Saint Girons, however, indicate that seasonal or individual variation in SSK hypertrophy may be more widespread in snakes than generally believed. We note that many of our specimens with inactive SSKs were undergoing spermiation in the testes but lacked sperm in the ductus epididymis. This may indicate some decoupling of testicular cycles and breeding activity. Perhaps, the SSK in some species first becomes active when sperm are stored in the ductus deferens.

Ultrastructure and Character Evolution

Two specimens of *L. colubrina*, sex unspecified, were among several reptiles whose kidney ultrastructure was studied by Schmidt-Nielsen and Davis (1968). They did not mention a SSK, but found that intercellular spaces in both PCT and DCT open when water and solute are resorbed in about the same concentrations as in the lumen. These spaces, however, are closed, when no transport takes place. In our specimens of *P. platurus*, the intercellular spaces are narrow with junctional complexes at the luminal end, whereas the basal end is widened, contains interdigitating lamellae, and is open to the lamina lucida. Thus, the

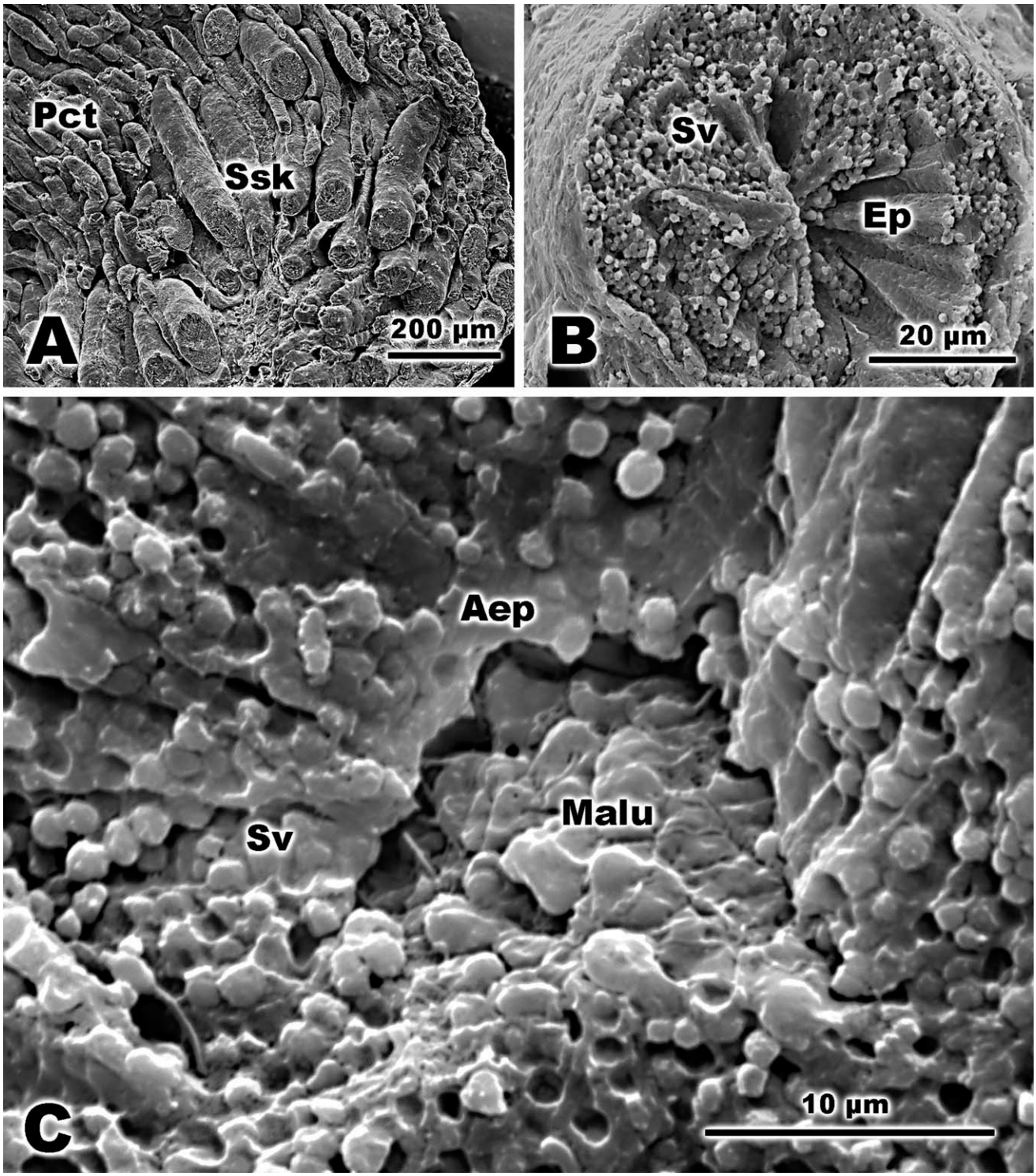

Fig. 7. Scanning electron micrographs of the sexual segment of a male *P. platurus* (SLU 133, 47.6-cm SVL). (**A**) Overview, showing sexual segment tubules (Ssk) mixed with proximal convoluted tubules (Pct). (**B**) Sexual segment tubule showing columnar epithelium (Ep) and secretory vacuoles (Sv) throughout the cells. (**C**) Luminal area of a sexual segment tubule showing secretory vacuoles protruding through the apical epithelium (Aep) and forming a matrix of secretory product in the lumen (Malu).

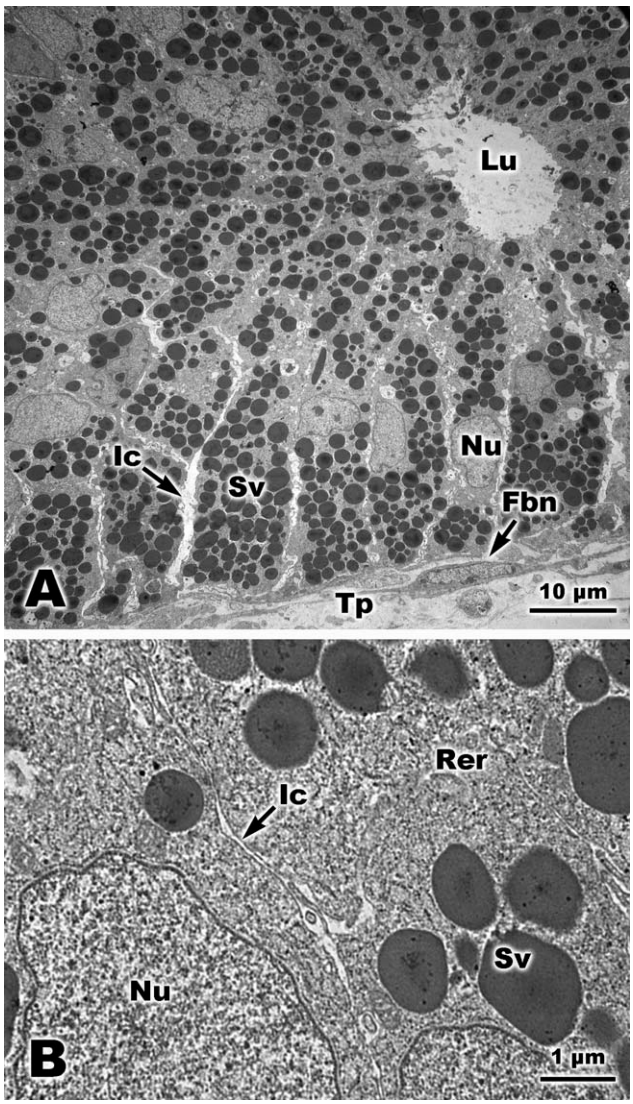

Fig. 8. Transmission electron micrographs through the sexual segment of a male *P. platurus* (SLU 138, 56.5-cm SVL). (**A**) Overview. Note mature secretory vacuoles (Sv) throughout epithelium, central nuclei (Nu) and wide intercellular canaliculi (Ic) especially basally. Lumen (Lu) appears evoid of secretory product. Fibroblasts, indicated by their nuclei (Fbn), appear in the tunica propria (Tp). (**B**) Detail of supranuclear among cytoplasm. Here, the intercellular canaliculi are narrow and lack junctional complexes. Rough endoplasmic reticulum (Rer) is abundant among secretory vacuoles (Sv).

intercellular canaliculi could be involved in transport of substances into or out of the epithelial cells of the SSK.

With the addition of *P. platurus*, the ultrastructure of the SSK has now been described for 10 species of squamates. The species for which ultrastructural studies have been done are, of course, few in number relative to the great diversity of squamates (some 9193 species, Reptile-Database, 2012), and they are not sister taxa. Thus, a phylogenetic study of cytological characters is premature. Some interesting observations, however, can be made.

Cytological characters that appear to be sympleisomorphies are those associated with simple columnar epithelium specialized for the secretion of a protein + carbohydrate product that matures and is released seasonally. The mode of secretion varies, although the most common mode is apocrine. The appearance of the mature secretory vacuoles also is quite variable and may be electron lucent as in *B. irregularis* (Siegel et al., 2009b); uniformly electron dense as in *S. pygaea* (Sever et al., 2002), *H. turcicus* (Rheubert et al., 2011), and *P. platurus*; biphasic as in *C. lemniscatus* (Del Conte and Tamayo, 1973), *N. natrix* (Kühnel and Krisch, 1974), *N. sipedon* (Krohmer, 2004), and *S. lateralis* (Sever and Hopkins, 2005); or consist of both electron lucent and electron dense vacuoles, as in *P. taurica* (Gabri, 1983) and *A. piscivorus* (Sever et al., 2008).

Convergence is apparent in the appearance of mature secretory vacuoles described above and in certain characters as well. Nuclei are basal in all taxa except in distantly related *P. platurus* and *S. pygaea* (Sever et al., 2002), in which nuclei are medial in the epithelial cells. Smooth endoplasmic reticulum has been reported in the epithelial cells of the SSK only in *Cnemidophorus leminiscatus* (Del Conte and Tamayo, 1973) and *N. natrix* (Kühnel and Krisch, 1974). SSK tubules have been found in females only in *C. leminiscatus* and *S. lateralis* (Sever and Hopkins, 2005).

A number of the species whose SSK has been examined by ultrastructure have unique, autapomorphic characters. For example, unique characters for *C. leminiscatus* include zonation of epithelial cells, lipid droplets in the epithelium, and lack of seasonal variation in cytology (Del Conte and Tamayo, 1973). *N. natrix* is the only species in which cilia have been reported (Kühnel and Krisch, 1974). *P. taurica* is the only species with more than one type of epithelial cell (Gabri, 1983). Interepithelial leukocytes have only been reported for *H. turcicus* (Rheubert et al., 2011). A constitutive secretory pathway was found only in *N. sipedon* (Krohmer, 2004).

A few characters may help define clades. The observation that the SSK contains, simple columnar epithelium in all squamates (although *P. taurica* has two types of these cells), is significant, because it distinguishes the SSK from kidney tubules in other amniotes, which are generally simple cuboidal or simple squamous (Fawcett, 1994), and it distinguishes the SSK from other parts of the nephron in squamates. The report of a lipid secretion into the lumen of the SSK in only two natricids, *Natrix natrix* (Kühnel and Krisch, 1974) and *Nerodia sipedon* (Krohmer, 2004), indicates that we should look for this product in other Natricidae, to see if it is a synapomorphy for the group. Likewise, the presence of narrow intercellular canaliculi in the natricids but widened intercellular canaliculi in other snakes may make this character (i.e., narrow intercellular canaliculi) a synapomorphy for the Natricidae within the Caenophidia. We have indicated earlier how the limitation of the SSK to the DCT is a synapomorphy for Alethinophidia (Henophidia + Caenophidia snakes). Finally, the maintenance of year-around hypertrophy of the SSKs in the three natricid snakes that have been examined in

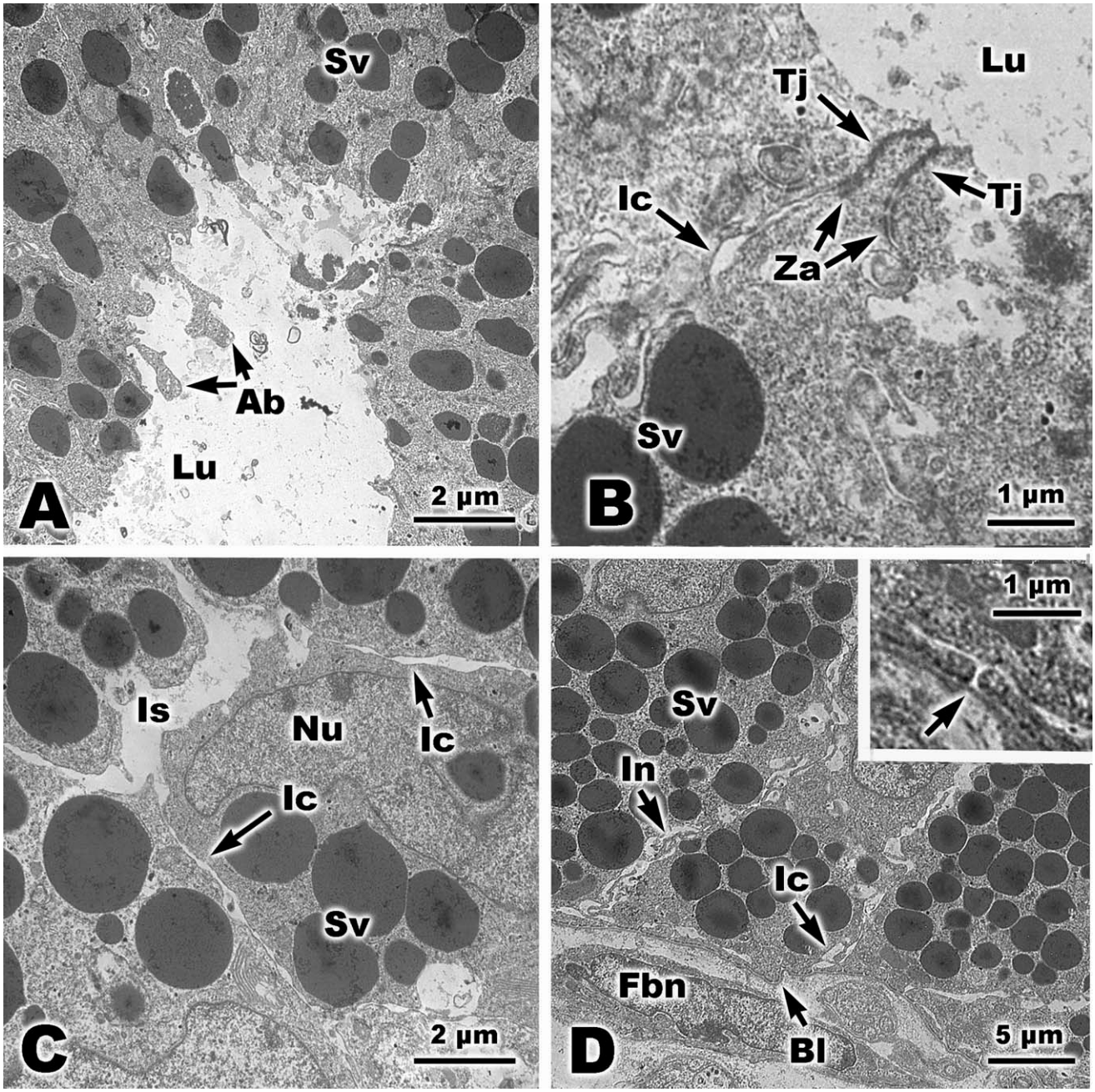

Fig. 9. Transmission electron micrographs through the sexual segment of a male *P. platurus* (SLU 138, 56.5-cm SVL). (**A**) Luminal border showing apical blebs (Ab). (**B**) Tight junctions (Tj) and zonula adherens (Za) at luminal border. Further distally, junctional complexes are not noticeable along the intercellular canaliculi (Ic). (**C**) The junction of two intercellular canaliculi (Ic) to form an intercellular space (Is). (**D**) Basal border showing interdigitating lamellae (In) in widened intercellular canaliculi. Arrow in inset indicates lack of junctional complexes between epithelial cells at their basal borders. Fbn = fibroblast nucleus; Lu = lumen; Nu = nucleus; Sv = secretory vacuoles.

ultrastructural studies is intriguing, but as discussed elsewhere, this character needs much more attention in snakes.

ACKNOWLEDGEMENT

The authors thank the students of Zoo 332 Animal Histology at SLU, who helped with the preparation of some tissues for this article.

LITERATURE CITED

Aldridge RD, Jellen BC, Siegel DS, Wisniewski SS. 2011. The sexual segment of the kidney. In: Aldridge RD, Sever DM, editors. Reproductive biology and phylogeny of snakes. Boca Raton, FL: CRC Press. p 477–509.

Bishop JE. 1959. A histological and histochemical study of the kidney tubules of the common garter snake, *Thamnophis sirtalis*, with special reference to the sexual segment in males. J Morphol 104:307–357.

Burbrink FT, Crother BI. 2011. Evolution and taxonomy of snakes. In: Aldridge RD, Sever DM, editors. Reproductive biology and phylogeny of snakes. Boca Raton, FL: CRC Press. p 19–53.

Courrier R. 1922. Etude préliminaire du déterminisme des charactères sexuels secondarires chez les poisons. Arch Anat Hist Embryol 1:115–144.

Cuellar O. 1966. Oviducal anatomy and sperm storage structures in lizards. J Morphol 119:7–20.

Del Conte E, Tamayo JG. 1973. Ultrastructure of the sexual segments of the kidneys in male and female lizards, *Cnemidophorus l. lemniscatus* (L.). Z Zellforsch Mikrosk Anat 144:325–327.

Devine MC. 1975. Copulatory plugs in snakes: enforced chastity. Science 187:844–845.

Fawcett DW. 1994. Bloom and Fawcett: a textbook of histology. 12th ed. New York: Chapman and Hall. 964 p.

Fox W. 1965. A comparison of the male urogenital systems of blind snakes, Leptotyphlopidae and Typhlopidae. Herpetologica 21: 241–256.

Furieri P, Lanzavecchia G. 1959. Le secrezione dell' epididimo e del rene sessuale nei rettili. Studio al microscopio elettronico. Arch Ital Anat Embriol 64:357–379.

Gabri MS. 1983. Seasonal changes in the ultrastructure of the kidney collecting tubules in the lizard *Podarcis* (= *Lacerta*) *taurica*. J Morphol 175:143–151.

Gampert O. 1866. Ueber die Niere von *Tropidonotus natrix* und der Cyprinoiden. Wissen Zool 16:369–373.

Hayat MA. 1993. Stains and cytochemical methods. New York: Plenum Press. 455 p.

Jakobsson S, Borg SB, Haux C, Hyllner SJ. 1999. An 11 keto-testosterone induced kidney-secreted protein: the nest building glue from the male threes pined stickleback, *Gasterosteous aculeatus*. Fish Physiol Biochem 20:79–85.

Krohmer RW. 2004. Variation in seasonal ultrastructure of sexual granules in the renal sexual segment of the northern water snake, *Nerodia sipedon sipedon*. J Morphol 261:70–80.

Kühnel W, Krisch B. 1974. On the sexual segment of the kidney in the snake (*Natrix natrix*). Cell Tissue Res 148:412–429.

Lukoschek V, Keogh JS. 2006. Molecular phylogeny of sea snakes reveals a rapidly diverged adaptive radiation. Biol J Linn Soc 89: 523–539.

Prasad MRN, Reddy PRK. 1972. Physiology of the sexual segment of the kidney in reptiles. Gen Comp Endocrinol 3(Suppl):649–662.

Pyron RA, Burbrink FT, Colli GR, de Oca ANM, Vitt LJ, Kuczynski CA, Weins JJ. 2011. The phylogeny of advanced snakes (Colubroidea), with discovery of a new subfamily and comparison of support for likelihood trees. Mol Phyl Evol 58:329–342.

Reptile-Database. 2012. Species numbers (as of 1 February 2012). Available at: http://www.reptile-database.org/.

Rheubert JL, Murray CM, Siegel DS, Babin J, Sever DM. 2011. The sexual segment of *Hemidactylus turcicus* and the evolution of sexual segment location in Squamata. J Morphol 272:802–813.

Saint Girons H. 1972. Morphologie comparée du segment sexuel du rein des squamates (Reptilia). Arch Anat Microsc Morphol Exp 61:243–266.

Scanlon JD, Lee MSY. 2011. The major clades of living snakes: morphological evolution, molecular phylogeny, and divergence dates. In: Aldridge RD, Sever DM, editors. Reproductive biology and phylogeny of snakes. Boca Raton, FL: CRC Press. p 55–95.

Schmidt-Nielsen B, Davis LE. 1968. Fluid transport and tubular spaces in reptilian kidneys. Science 159:1105–1108.

Sever DM, Freeborn LR. 2012. Observations on the anterior testicular ducts in snakes with emphasis on sea snakes and ultrastructure in the Yellow-Bellied Sea Snake, *Pelamis platurus*. J Morphol 273:324–336.

Sever DM, Hopkins WA. 2005. Renal sexual segment of the ground skink, *Scincella laterale* (Reptilia, Squamata, Scincidae). J Morphol 266:46–59.

Sever DM, Siegel DS, Bagwill A, Eckstut ME, Alexander L, Camus A, Morgan C. 2008. Renal sexual segment of the Cottonmouth snake, *Agkistrodon piscivorus* (Reptilia, Squamata, Viperidae). J Morphol 269:640–653.

Sever DM, Stevens RA, Ryan TJ, Hamlett WC. 2002. Ultrastructure of the reproductive system of the black swamp snake (*Seminatrix pygaea*). III. Sexual segment of the male kidney. J Morphol 252: 238–254.

Siegel DS, Aldridge RD, Clark CS, Poldemann EH, Gribbins KM. 2009b. Stress and reproduction in the brown treesnake (*Boiga irregularis*) with notes on the ultrastructure of the sexual segment of the kidney in squamates. Can J Zool 87:1138–1146.

Siegel DS, Sever DM, Aldridge RD. 2010. The pelvic kidney of male *Ambystoma maculatum* (Amphibia, Urodela, Ambystomatidae) with special reference to the sexual collecting ducts. J Morphol 271:1422–1439.

Siegel DS, Sever DM, Rheubert JL, Gribbins KM. 2009a. Reproductive biology of *Agkistrodon piscivorus* Lacépède (Squamata, Serpentes, Viperidae, Crotalinae). Herpetol Monogr 23:74–107.

Smith MA. 1926. Monograph of the sea snakes (Hydrophiidae). London: Taylor and Francis.

Vitt LJ, Caldwell JP. 2009. Herpetology: an introductory biology of amphibians and reptiles. 3rd ed. San Diego: Academic Press. 720 p.

Volsøe H. 1944. Structure and seasonal variation of the male reproductive organs of *Vipera berus* (L.). Spolia Zool Musei Haun 5: 1–157.